Organogenèse
et Anatomie du Péritoine

Michel Montaudon

Berrettini de Cortone 1741

michel.montaudon@chu-bordeaux.fr

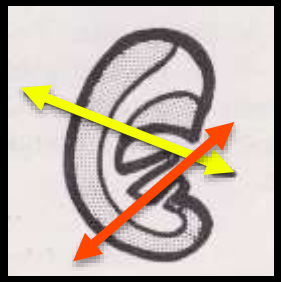



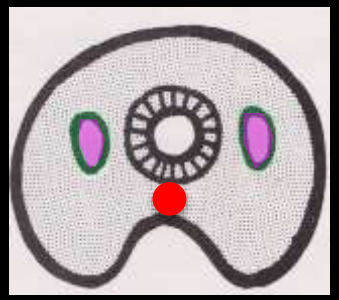

tube dig.

cavités cœlomiques droite et gauche

aorte

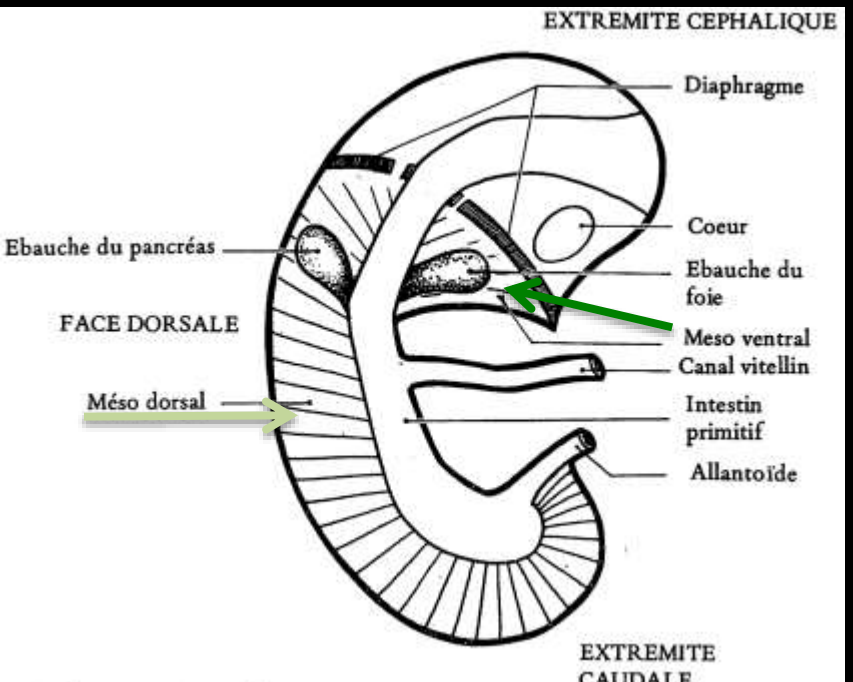



intestin ant.

intestin moy. et post.

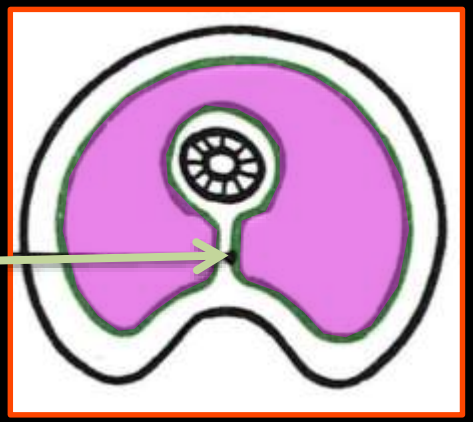

périt. viscéral

périt. pariétal

méso antérieur

méso postérieur

périt. viscéral et pariétal en continuité

cavité péritonéale

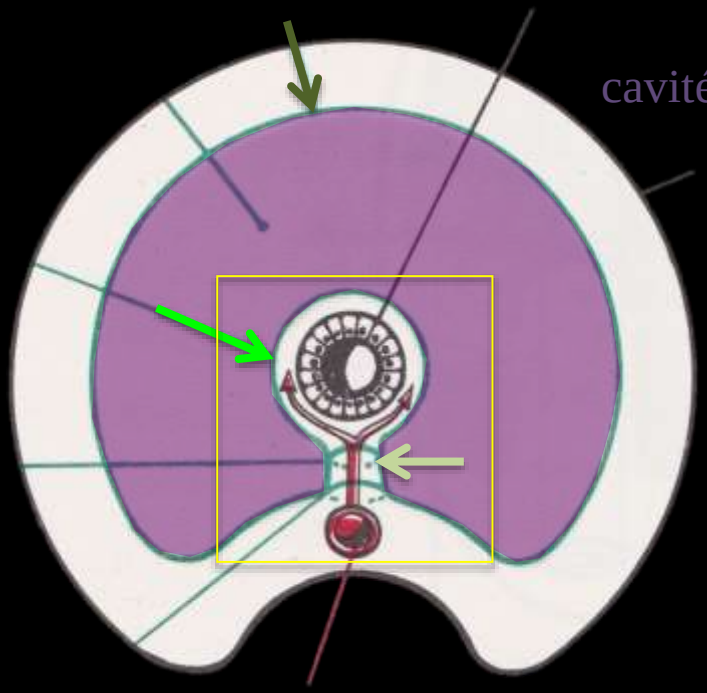

cavité péritonéale

périt. viscéral

périt. pariétal

méso postérieur

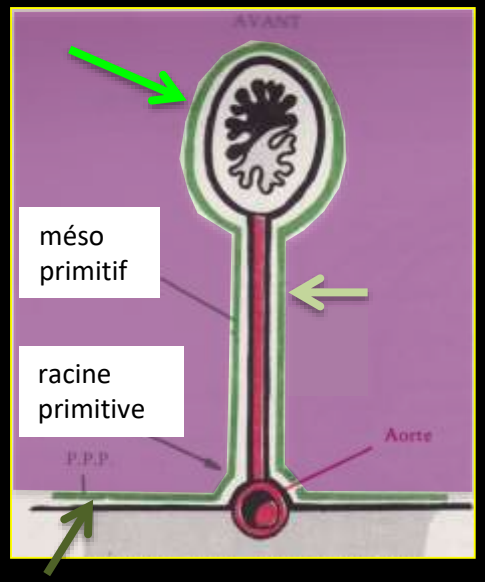

périt. viscéral et pariétal en continuité



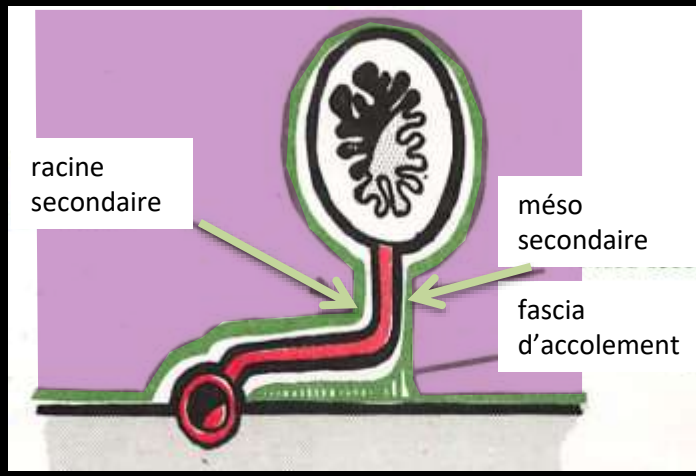

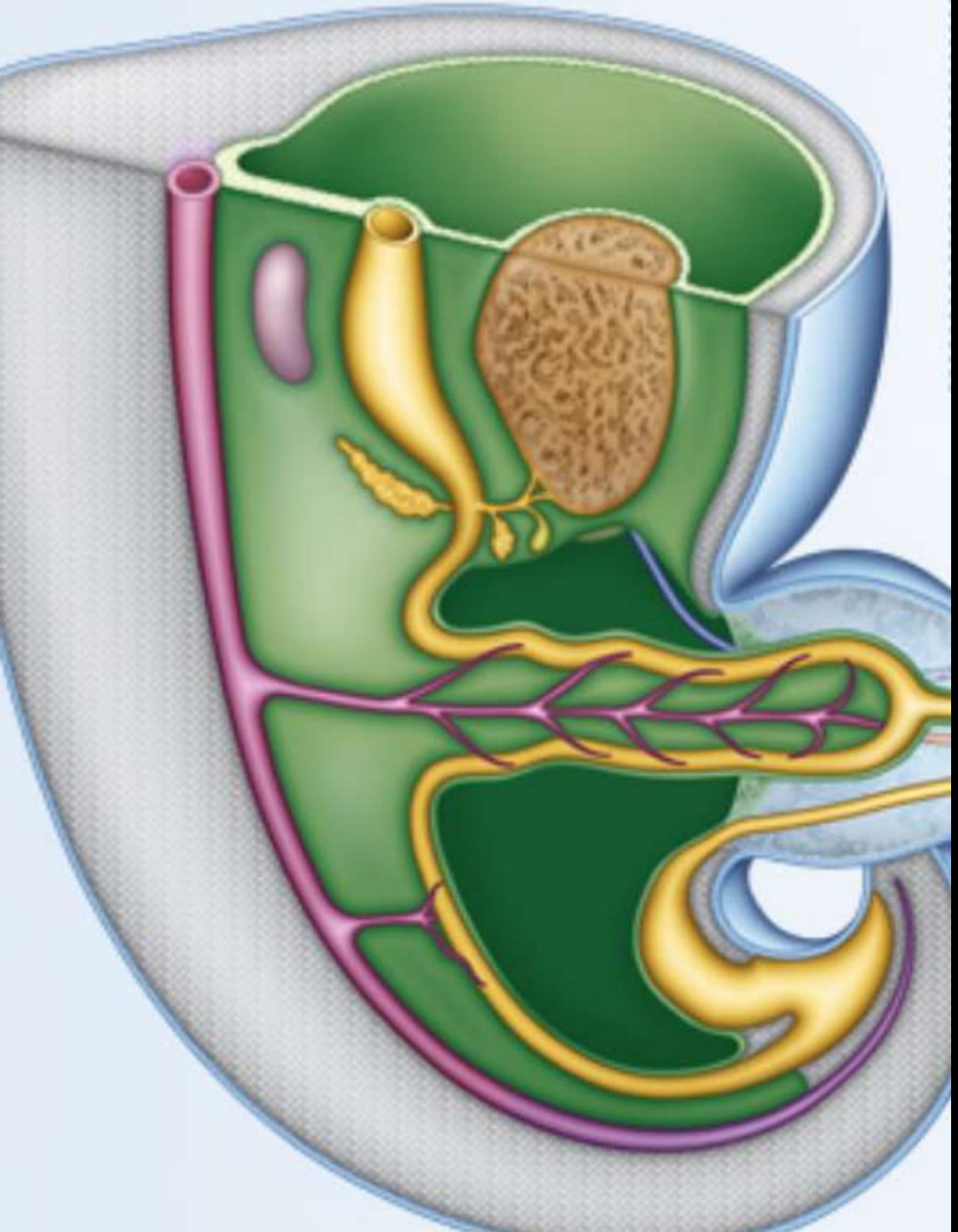

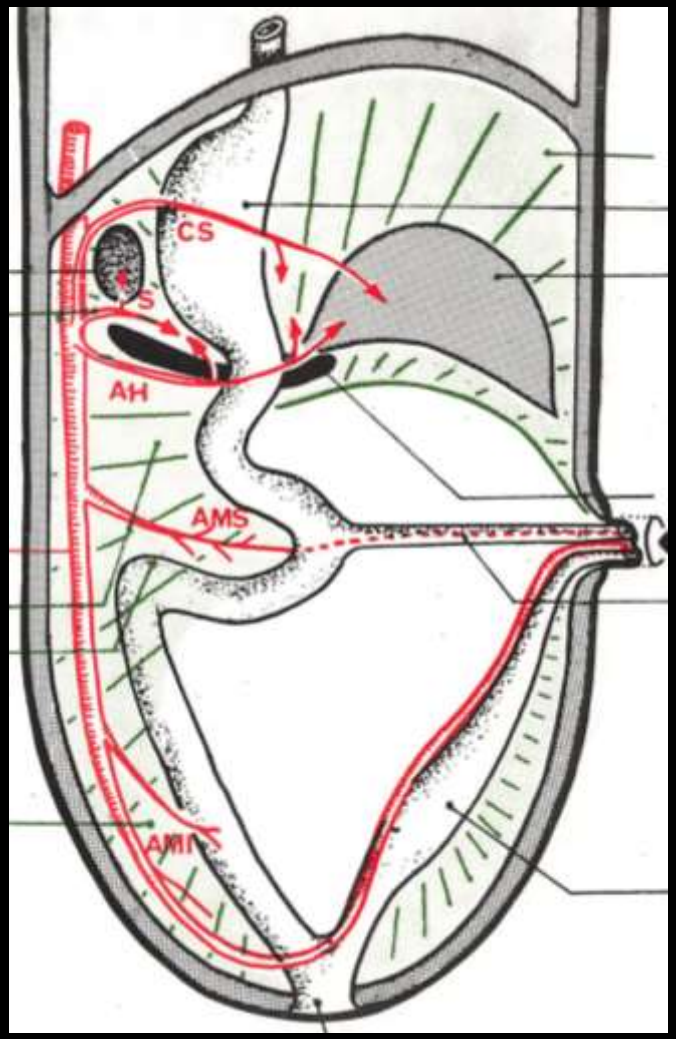

- étage supérieur: a. cœliaque
- étage moyen: a. MS
- étage inférieur: a. MI
- plancher

http://cvirtuel.cochin.univ-paris5.fr/Embryologie/

Etage supérieur (tronc cœliaque) formation des bourses omentale et épiploïque

croissance du foie + rotation de l'estomac

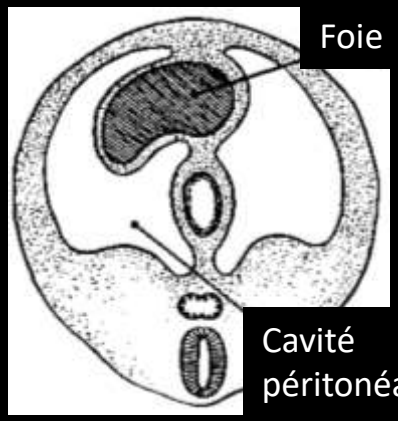

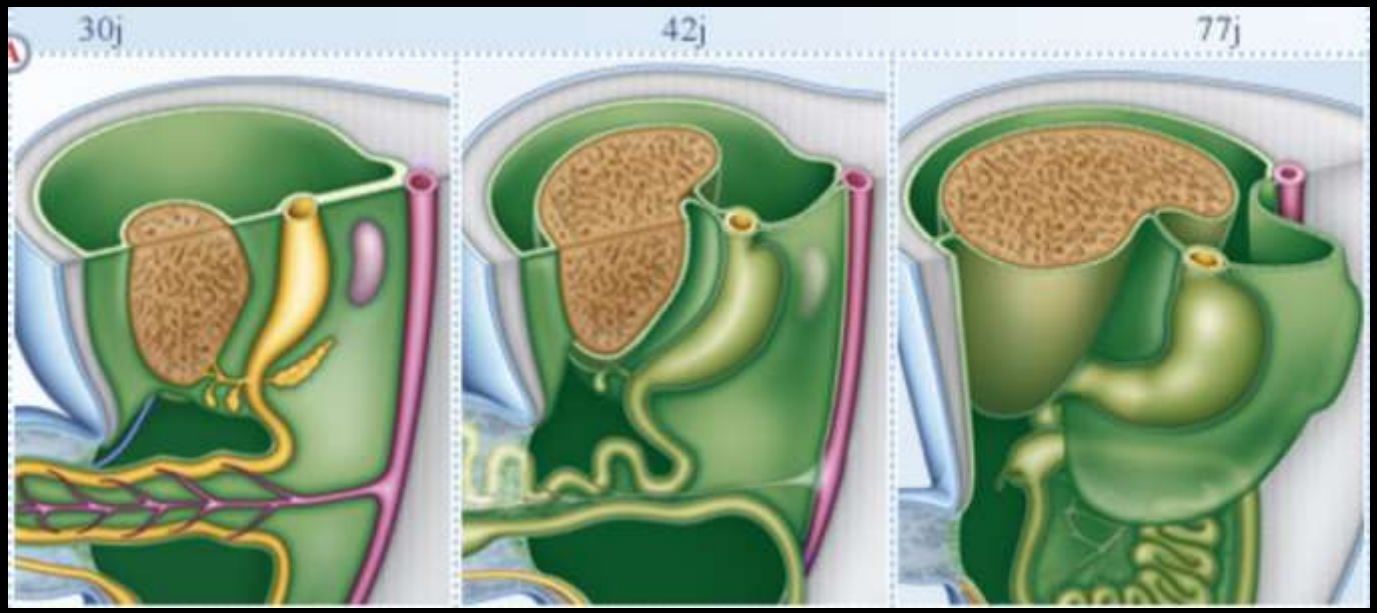

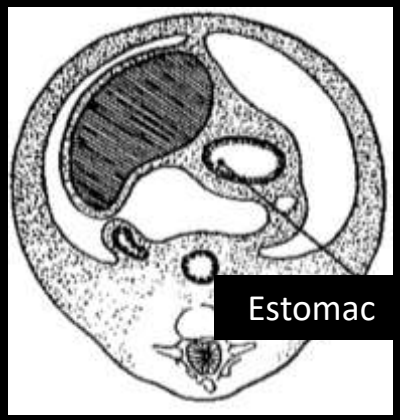

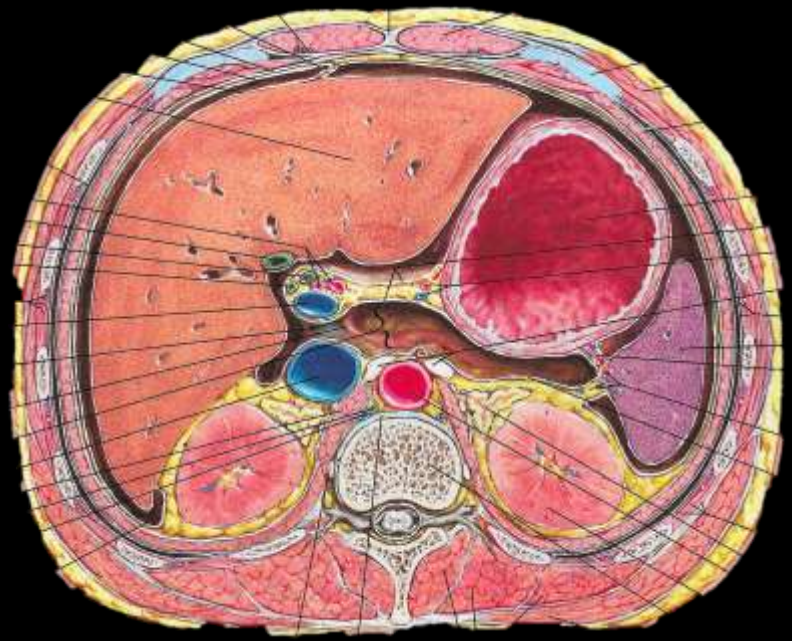

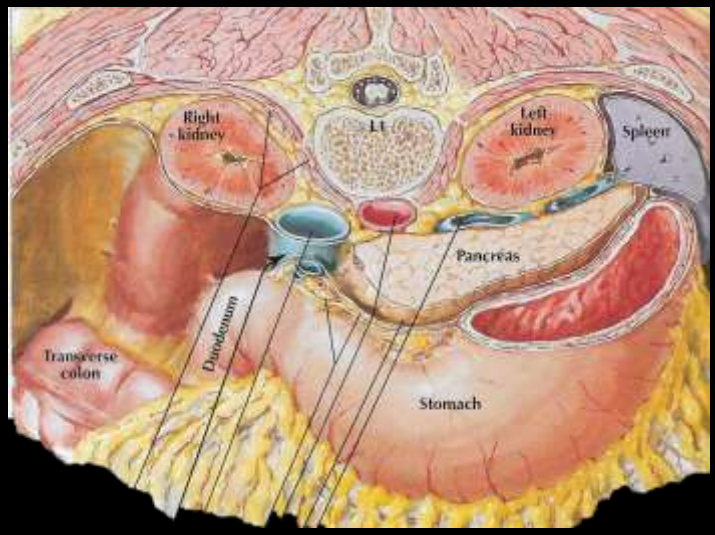

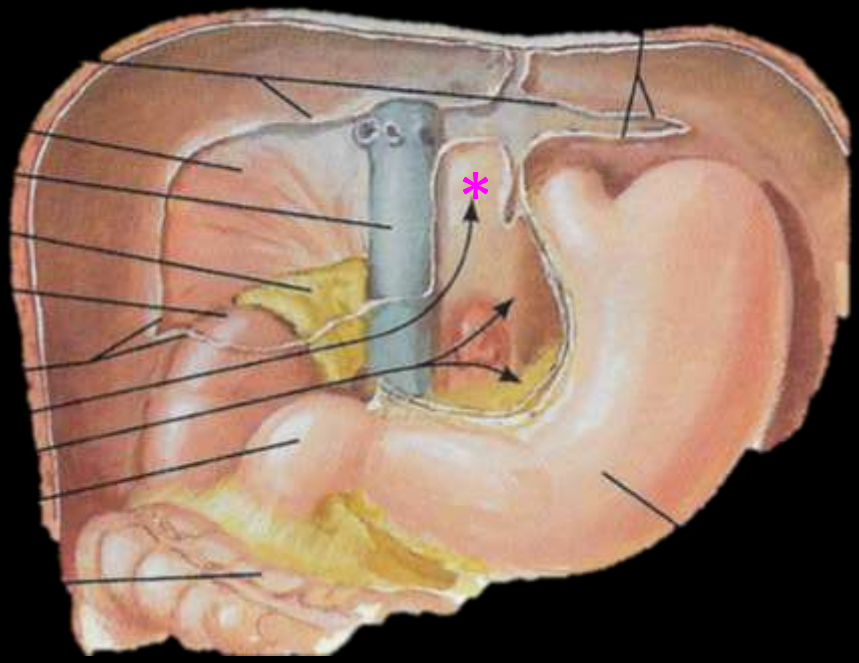

- récessus supérieur de la bourse omentale

- récessus inférieur de la bourse omentale (bourse épiploïque)

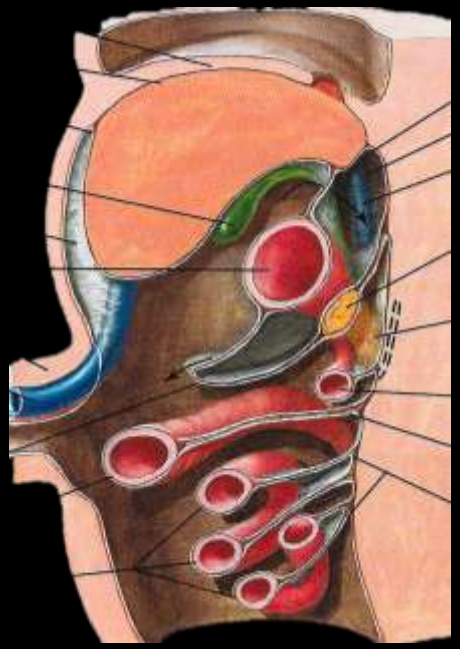

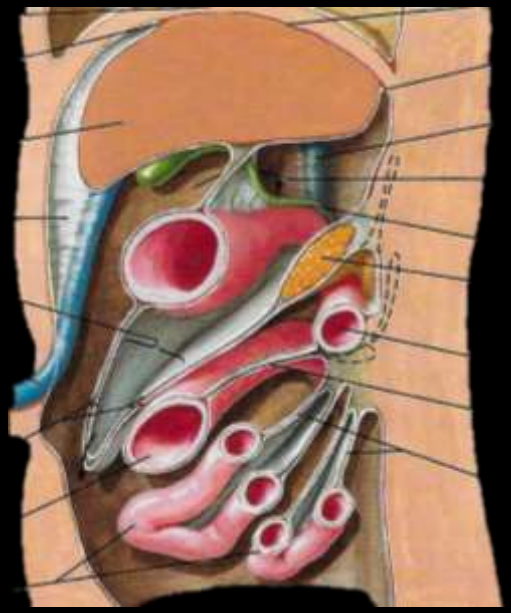

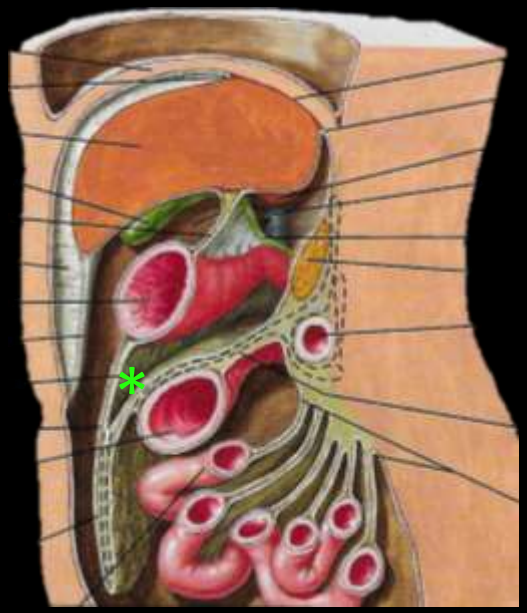

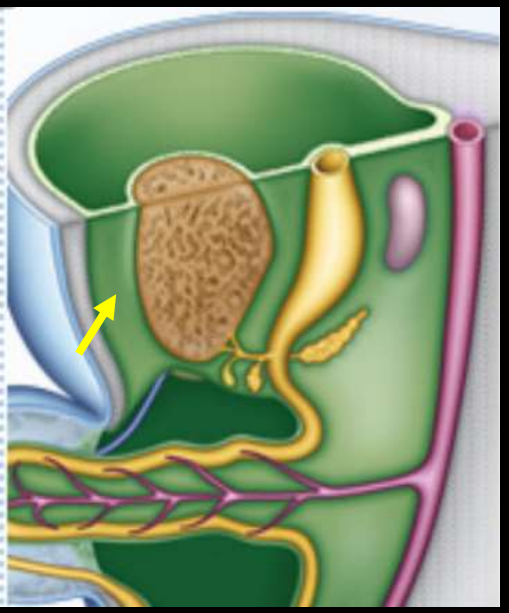

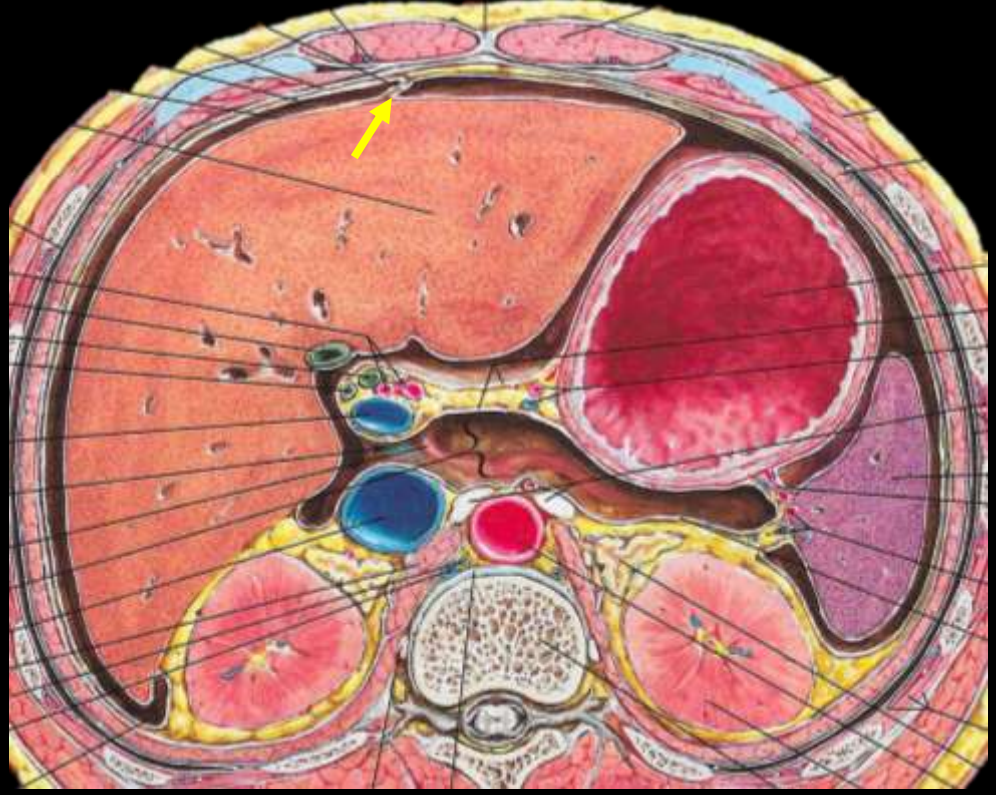

cloisons:

l. falciforme et l. rond

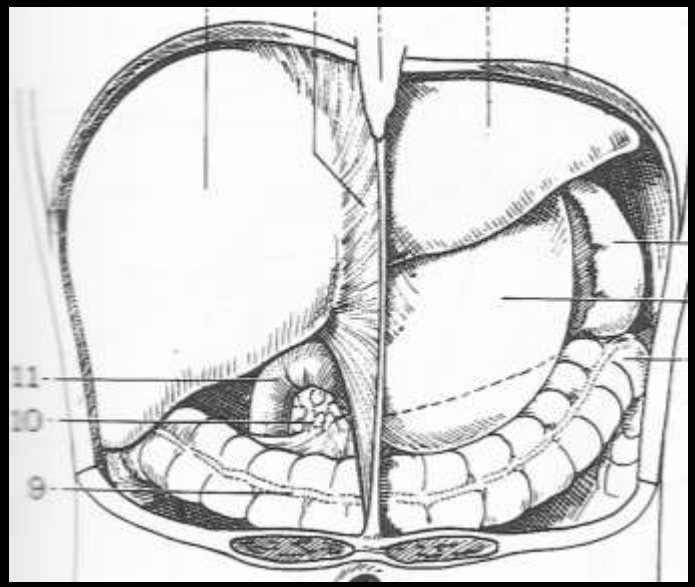

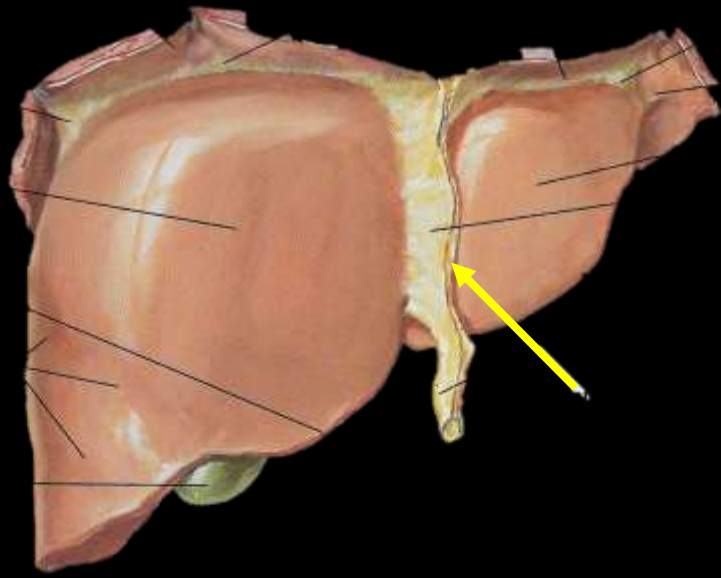

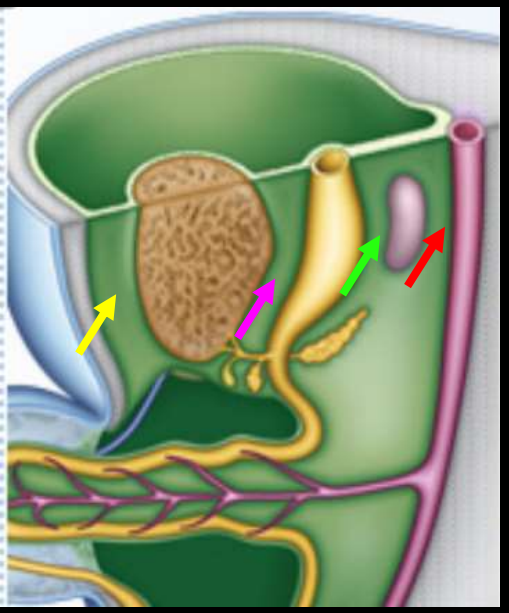

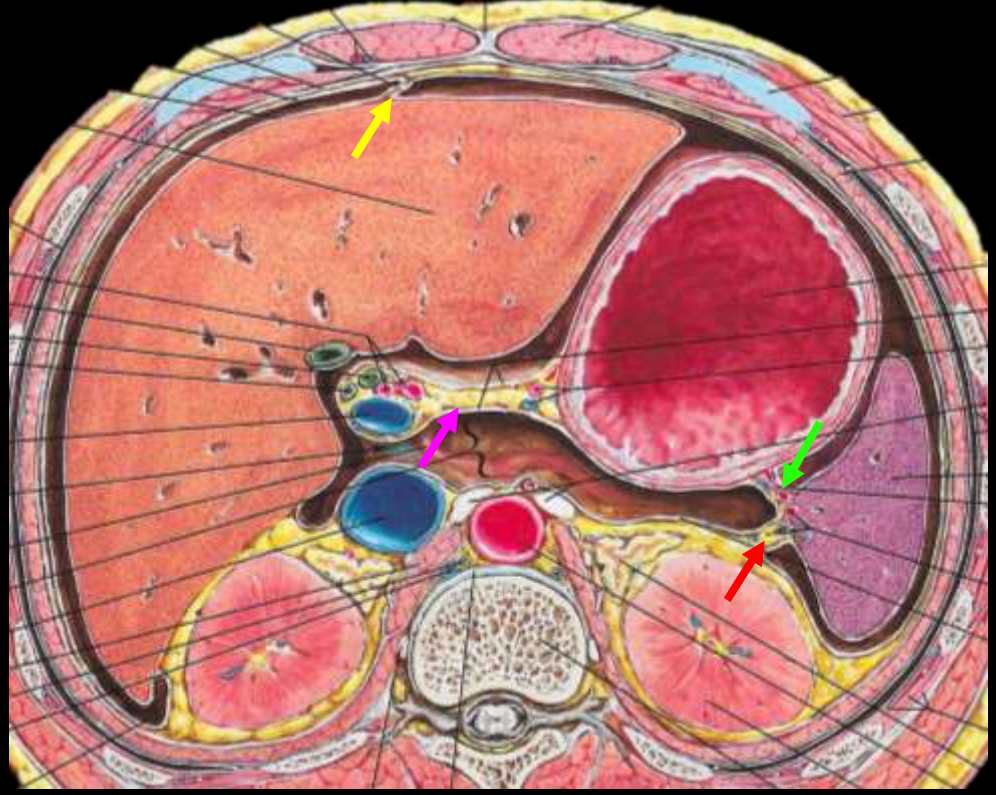

cloisons:

l. falciforme et l. rond

petit omentum (gastro-duodéno-hépatique)

l. gastro-splénique

l. pancréatico-splénique

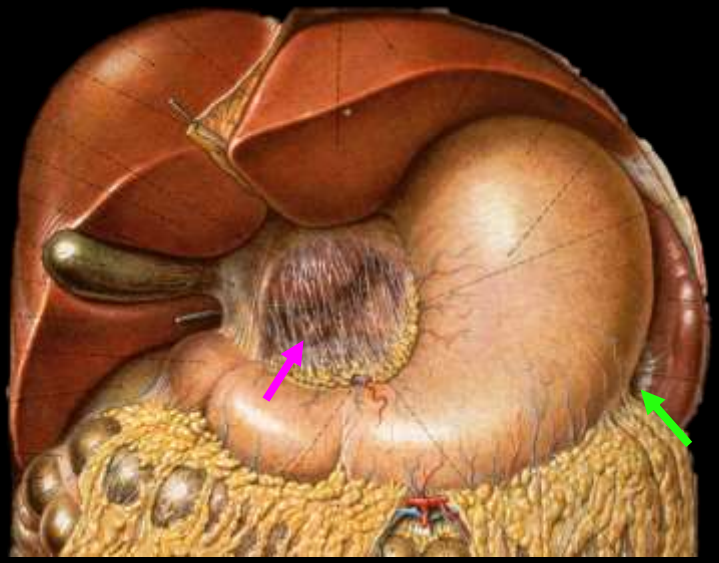

accolements: fascia rétro-pancréatique de Treitz

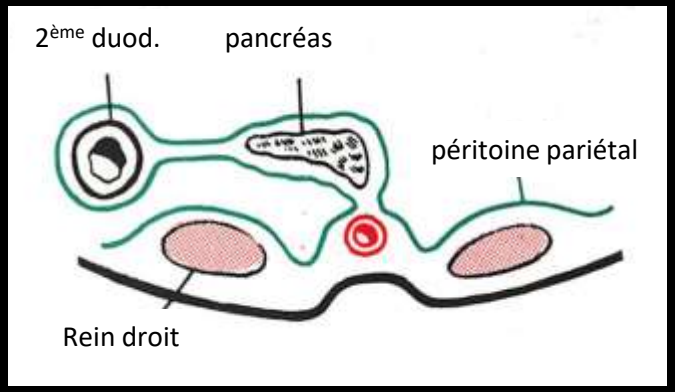

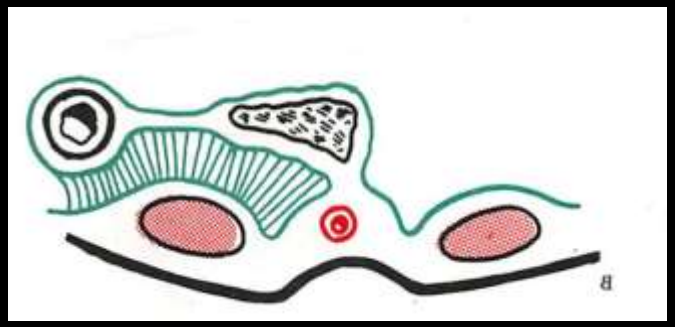

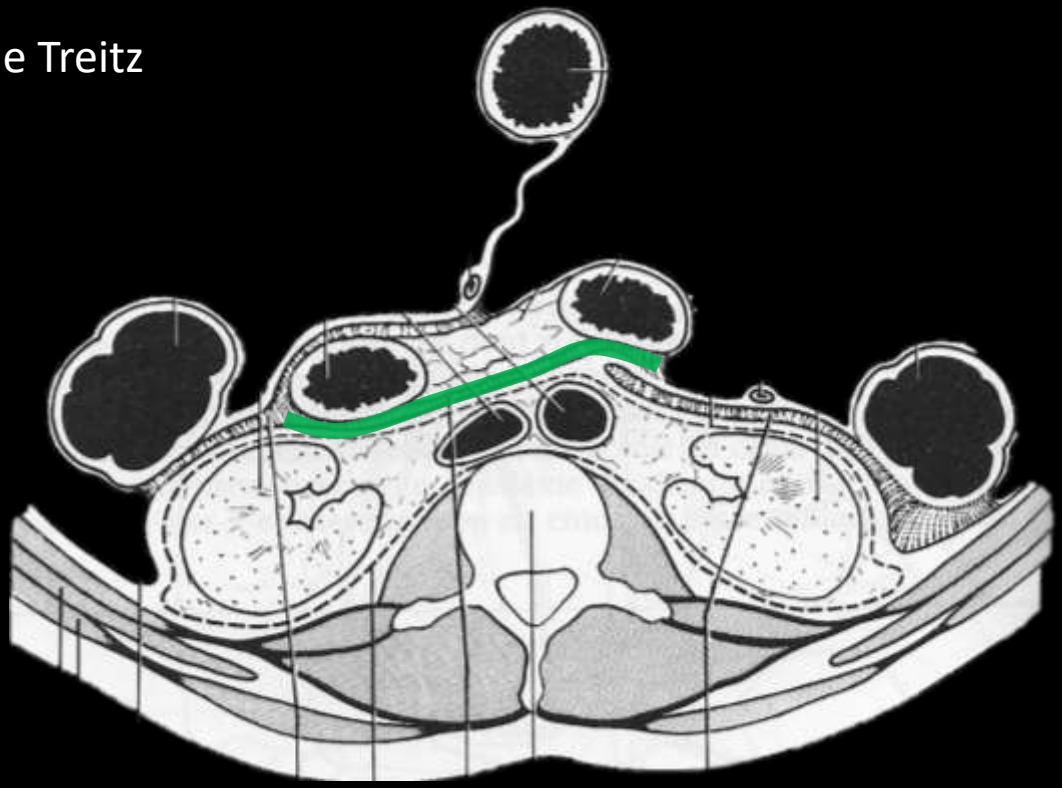

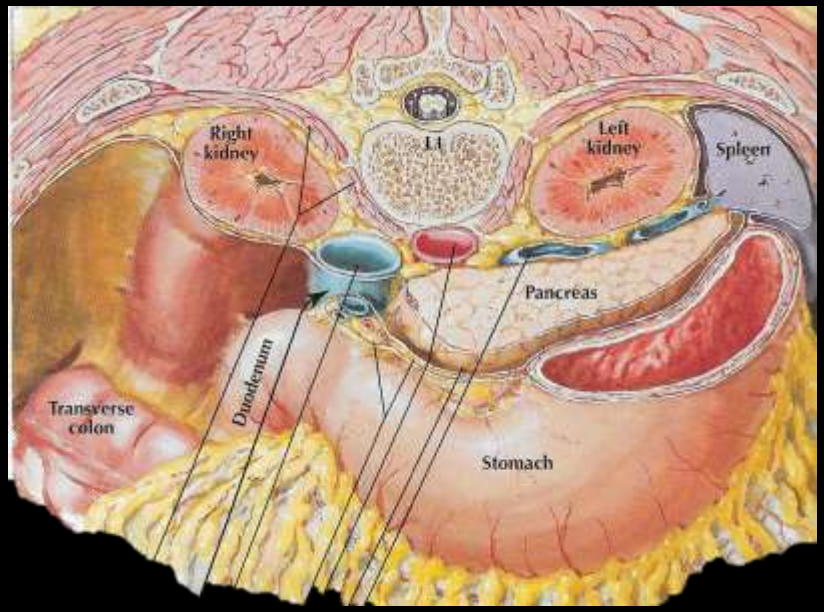

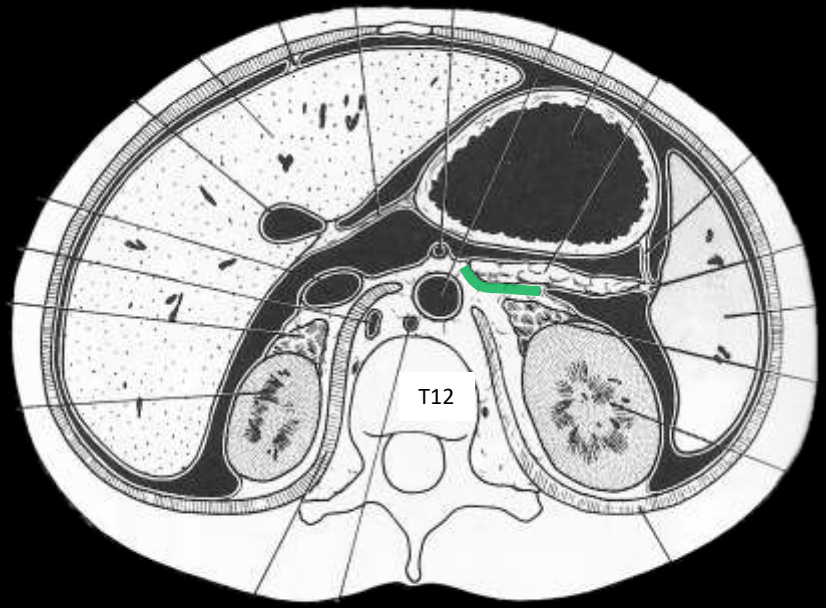

accolements: l. gastro-phrénique

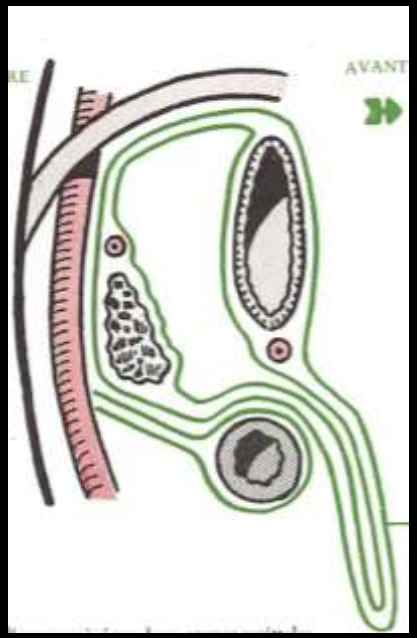

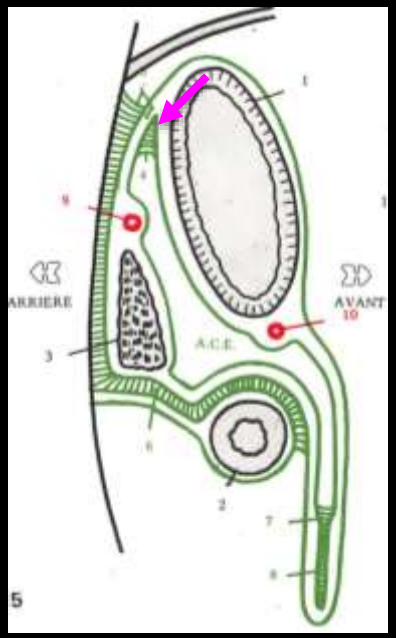

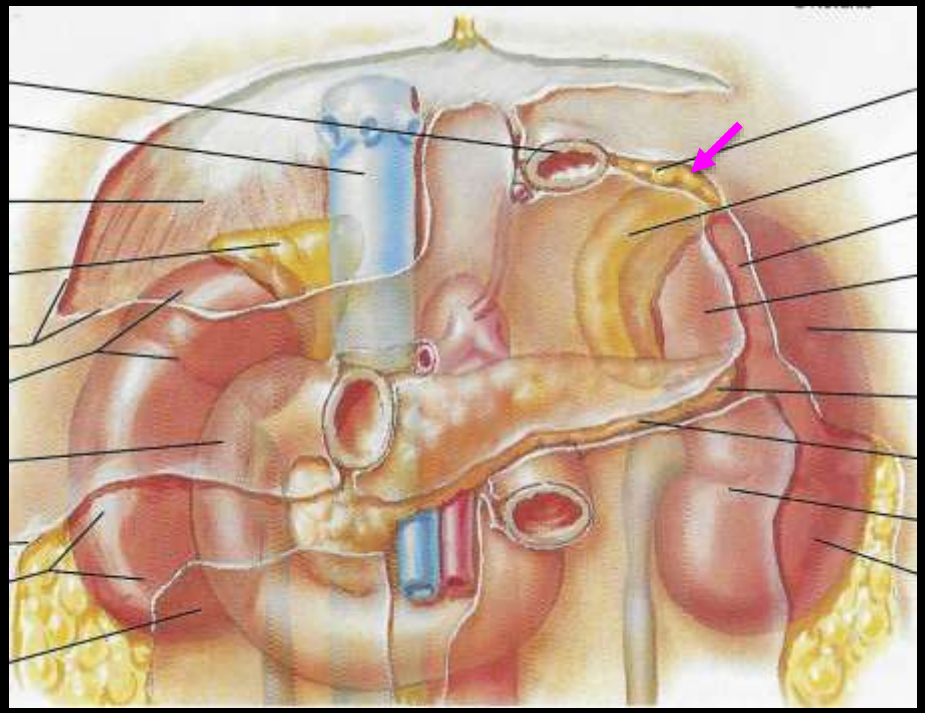

l. gastro-colique

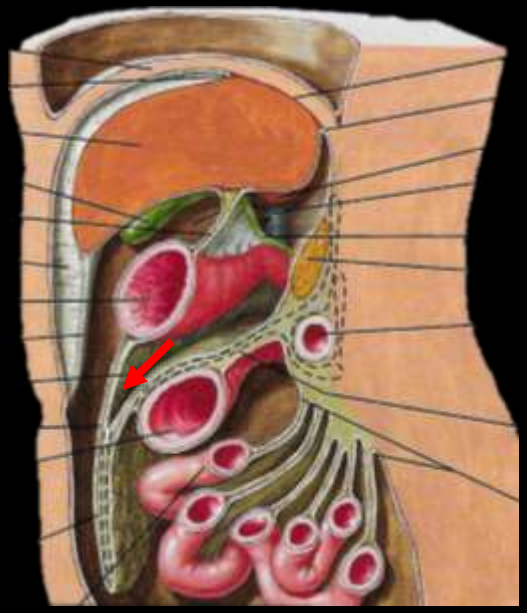

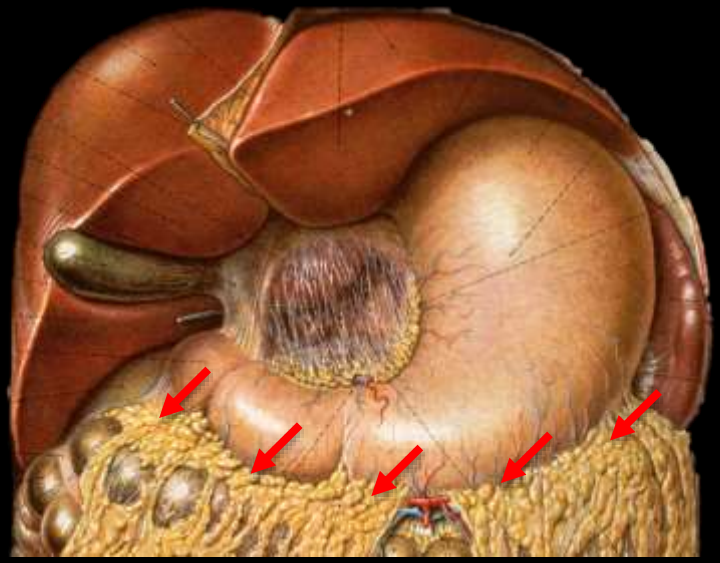

l. phrénico-colique

accolements: l. coronaire, ll. triangulaires (area nuda)

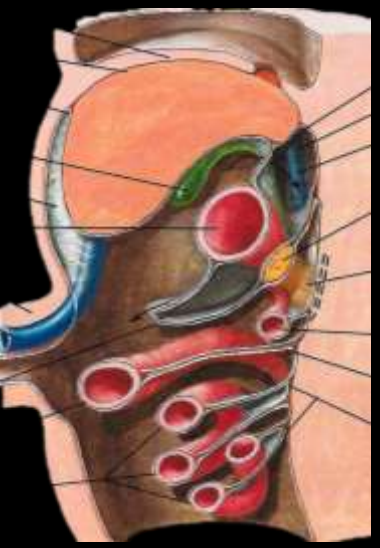

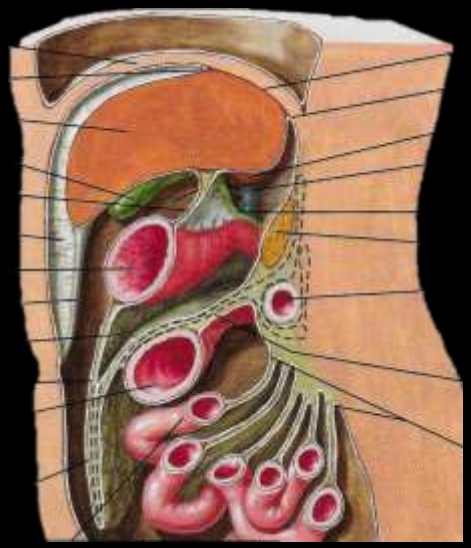

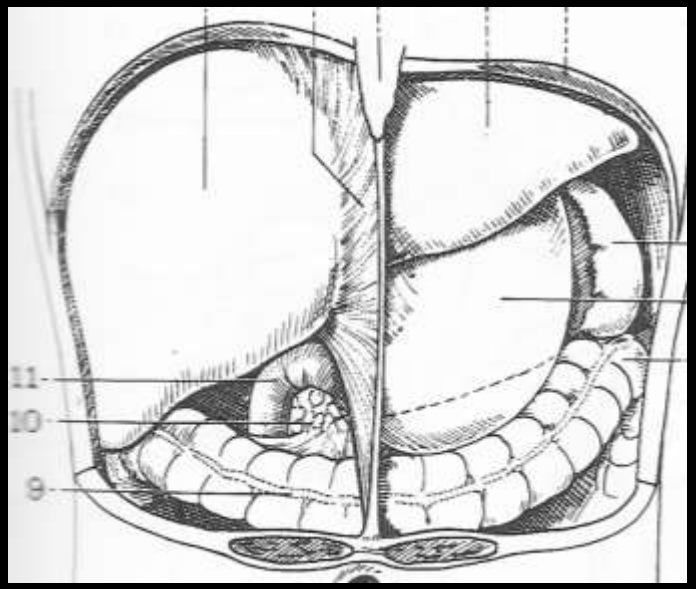

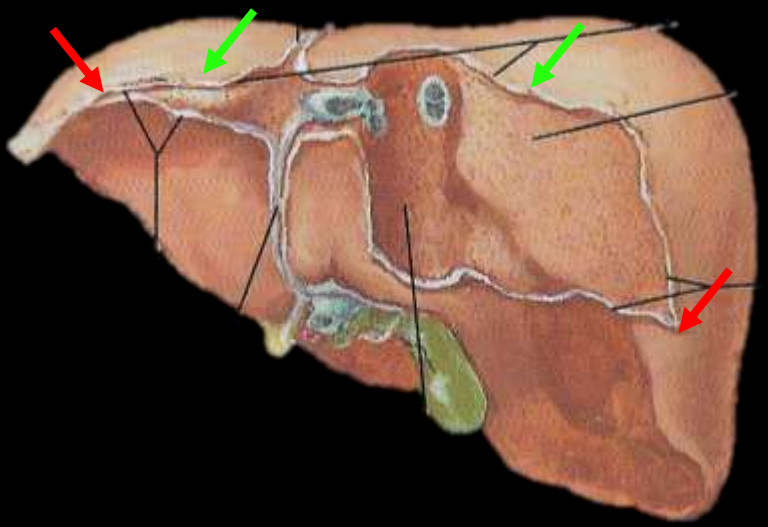

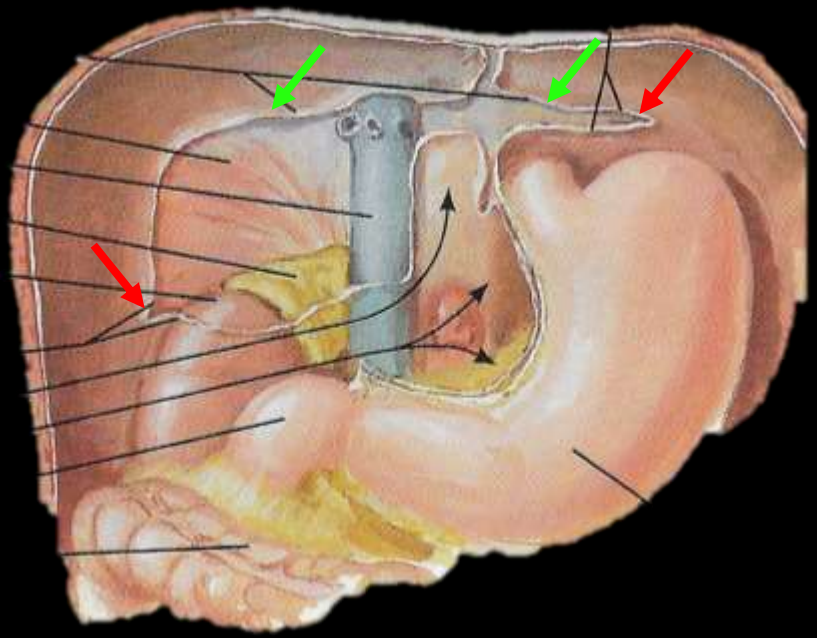

Etage moyen (a. mésentérique supérieure) rotation + croissance de l'anse intestinale

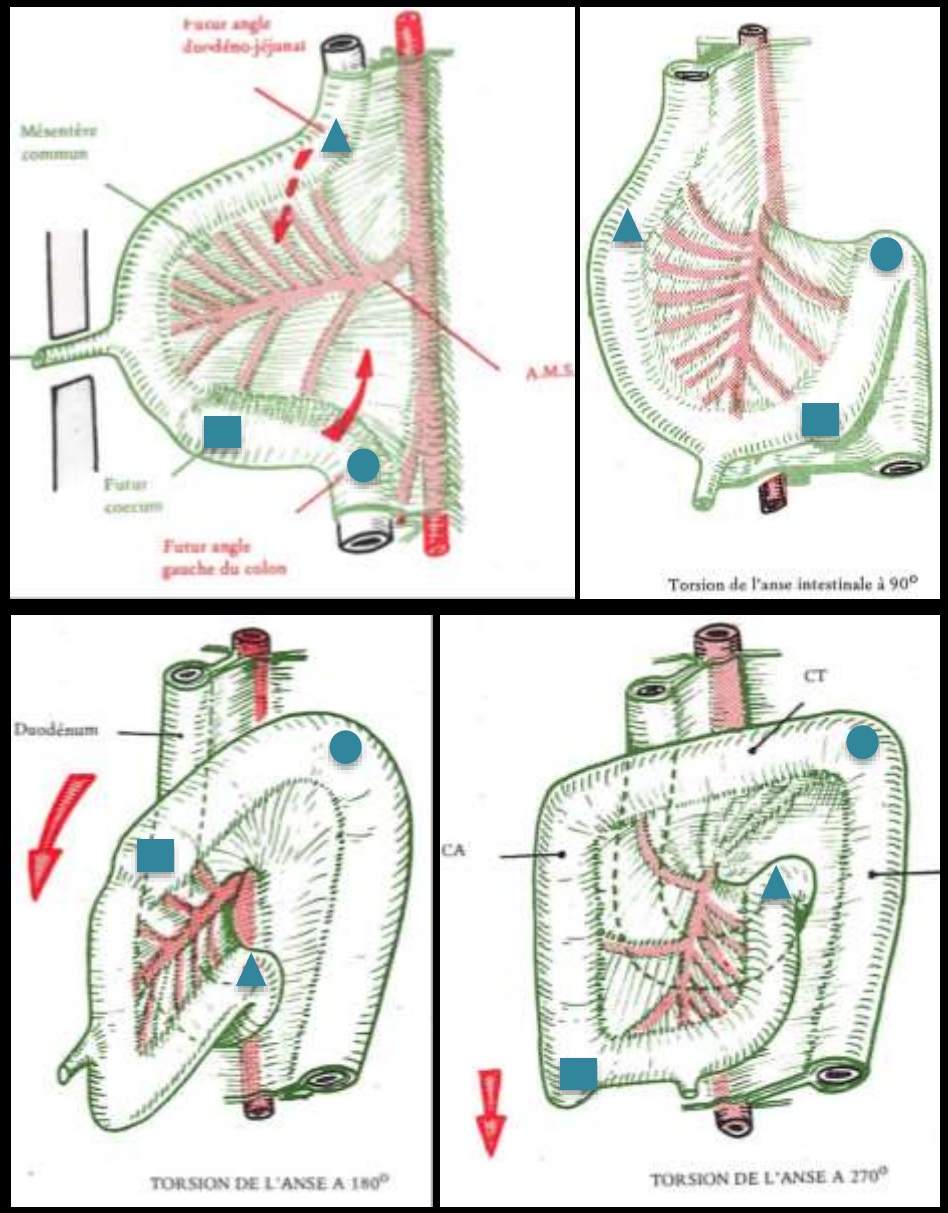

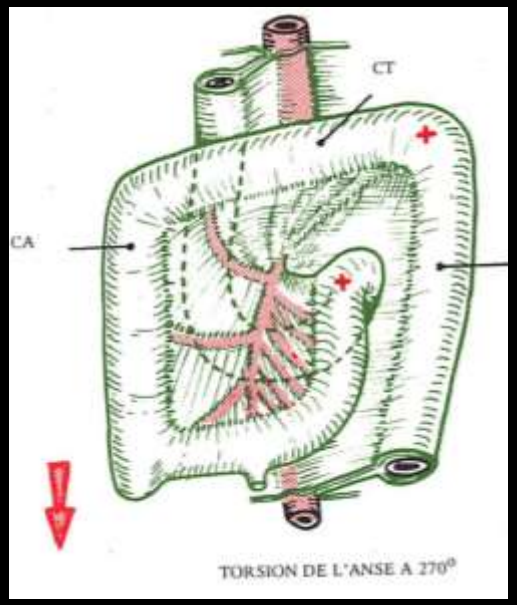

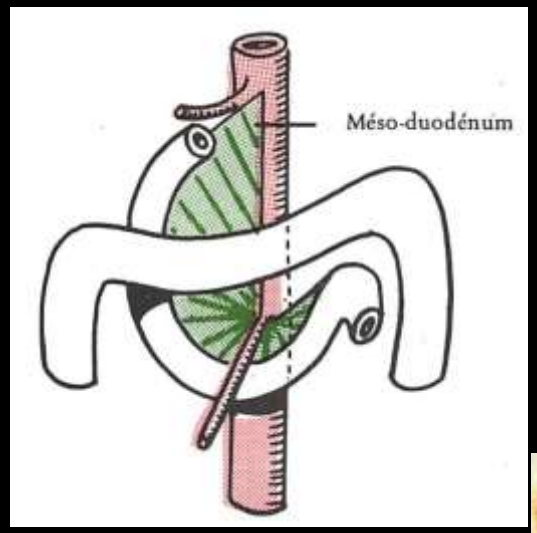

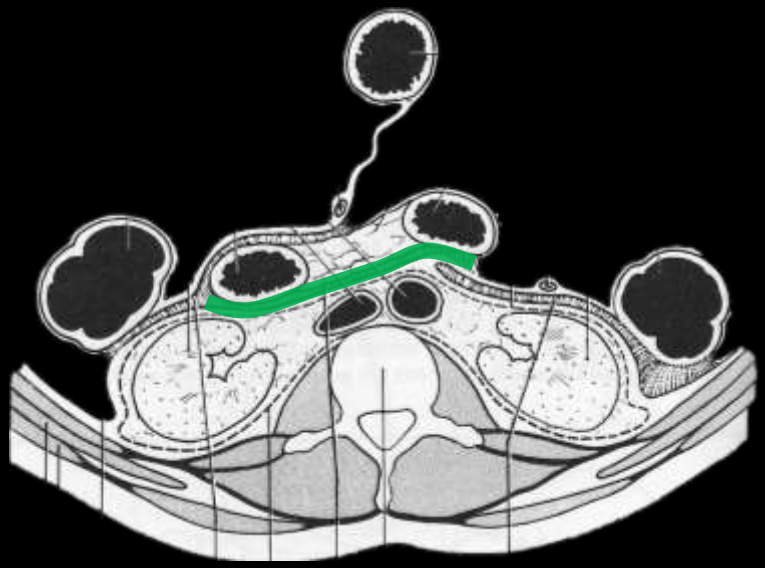

plis et fosses duodénales

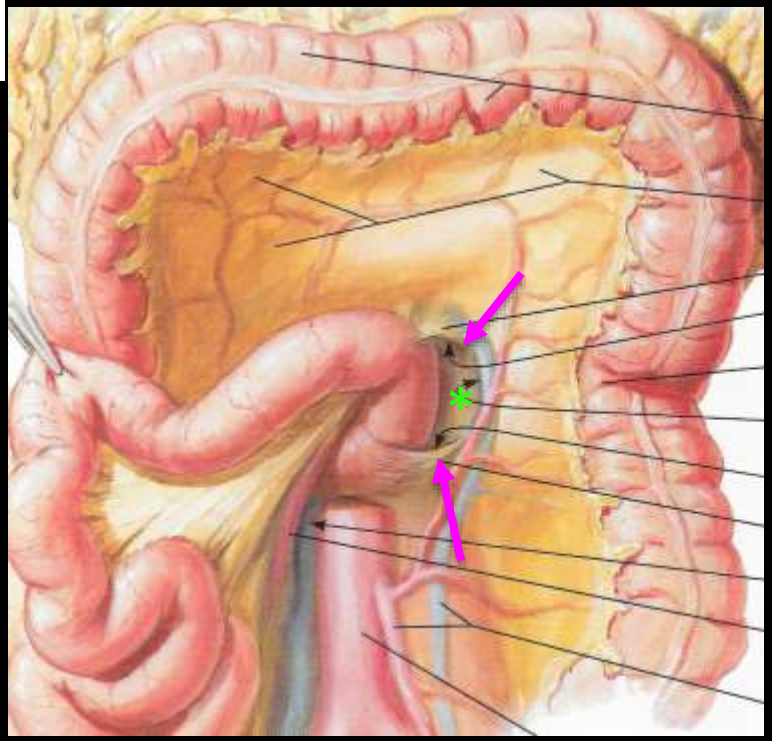

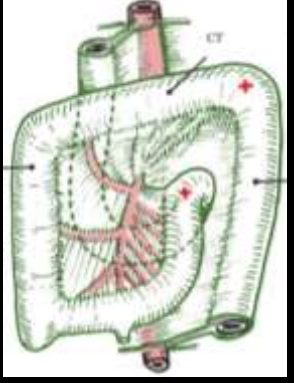
CT

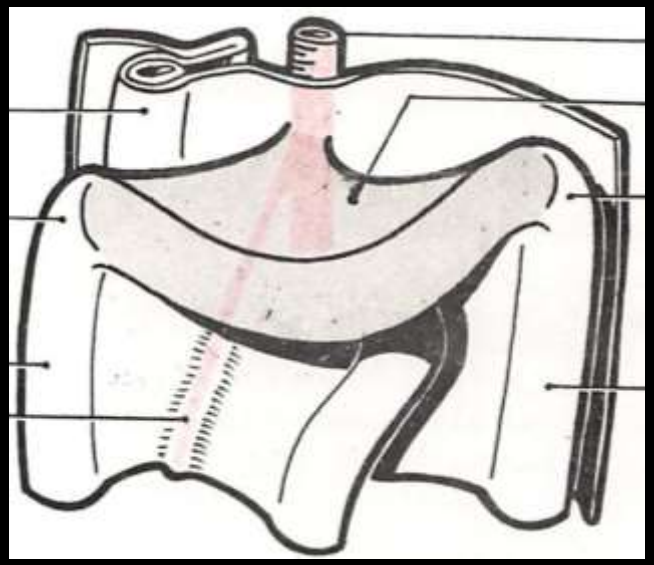

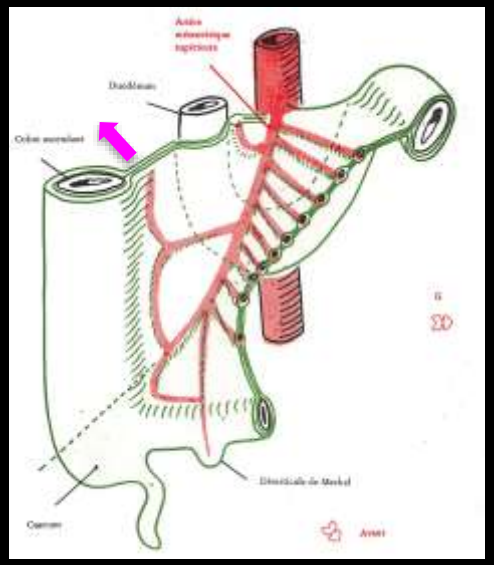
Duodénum
Côlon ascendant
Diverticule de Meckel
Caecum
Anus

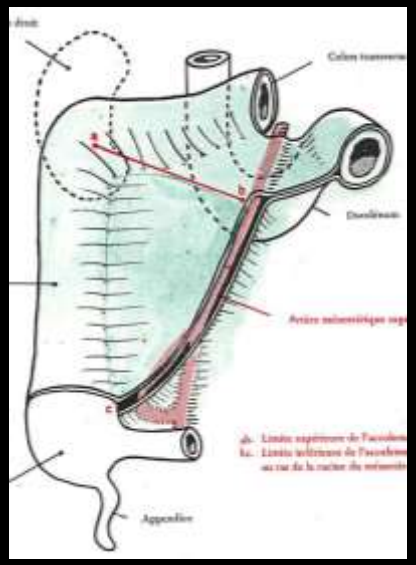
Côlon transverse
Duodénum
Appendice

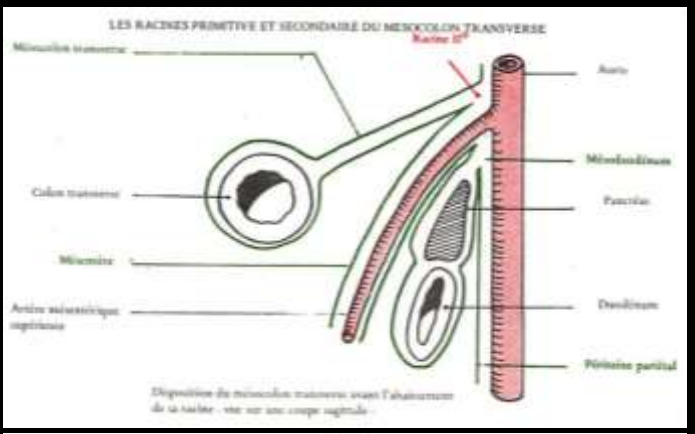
LES RACINES PRIMITIVE ET SECONDAIRE DU MESOCOLON TRANSVERSE
Racine II°
Aorte
Mésoduodénum
Côlon transverse
Pancréas
Mésentère
Duodénum
Péritoine pariétal

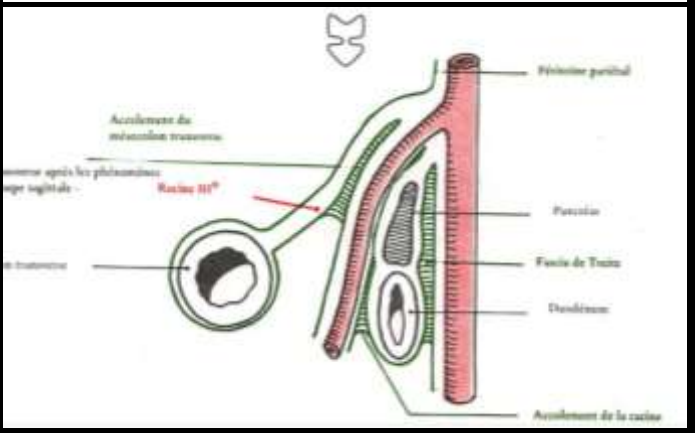
Péritoine pariétal
Accolement du mésocôlon transverse
Racine III°
Pancréas
Fascia de Treitz
Duodénum
Accolement de la racine

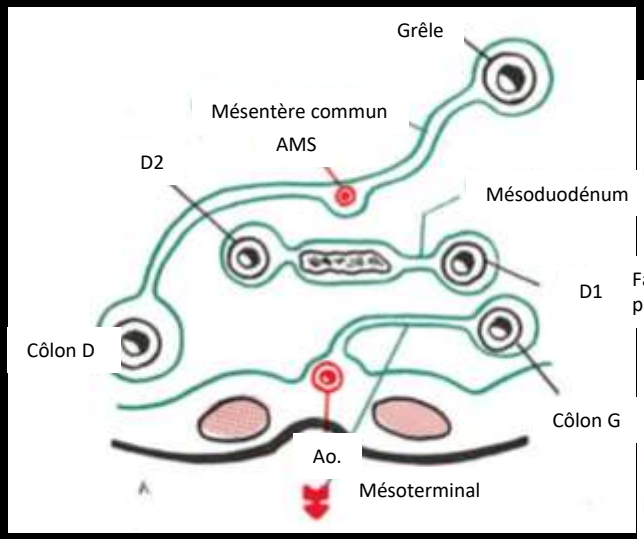
Grêle
Mésentère commun
AMS
D2
Mésoduodénum
D1
Côlon D
Côlon G
Ao.
Mésoterminal

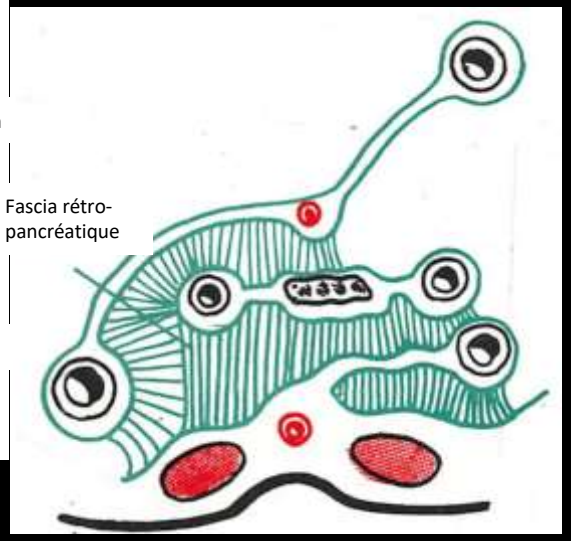
Fascia rétro-
pancréatique

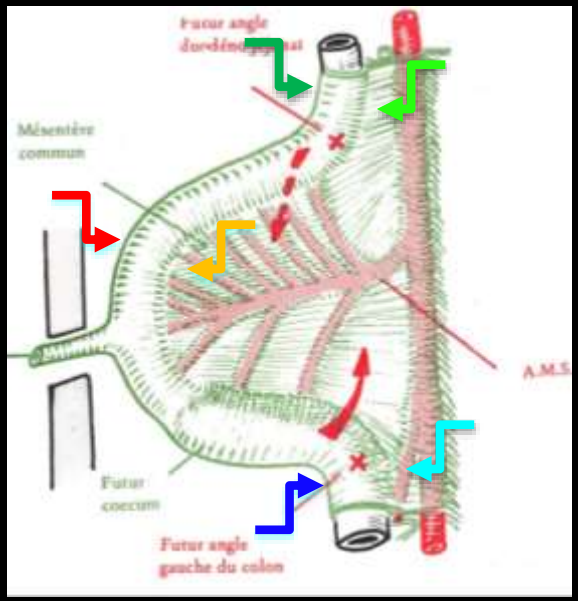

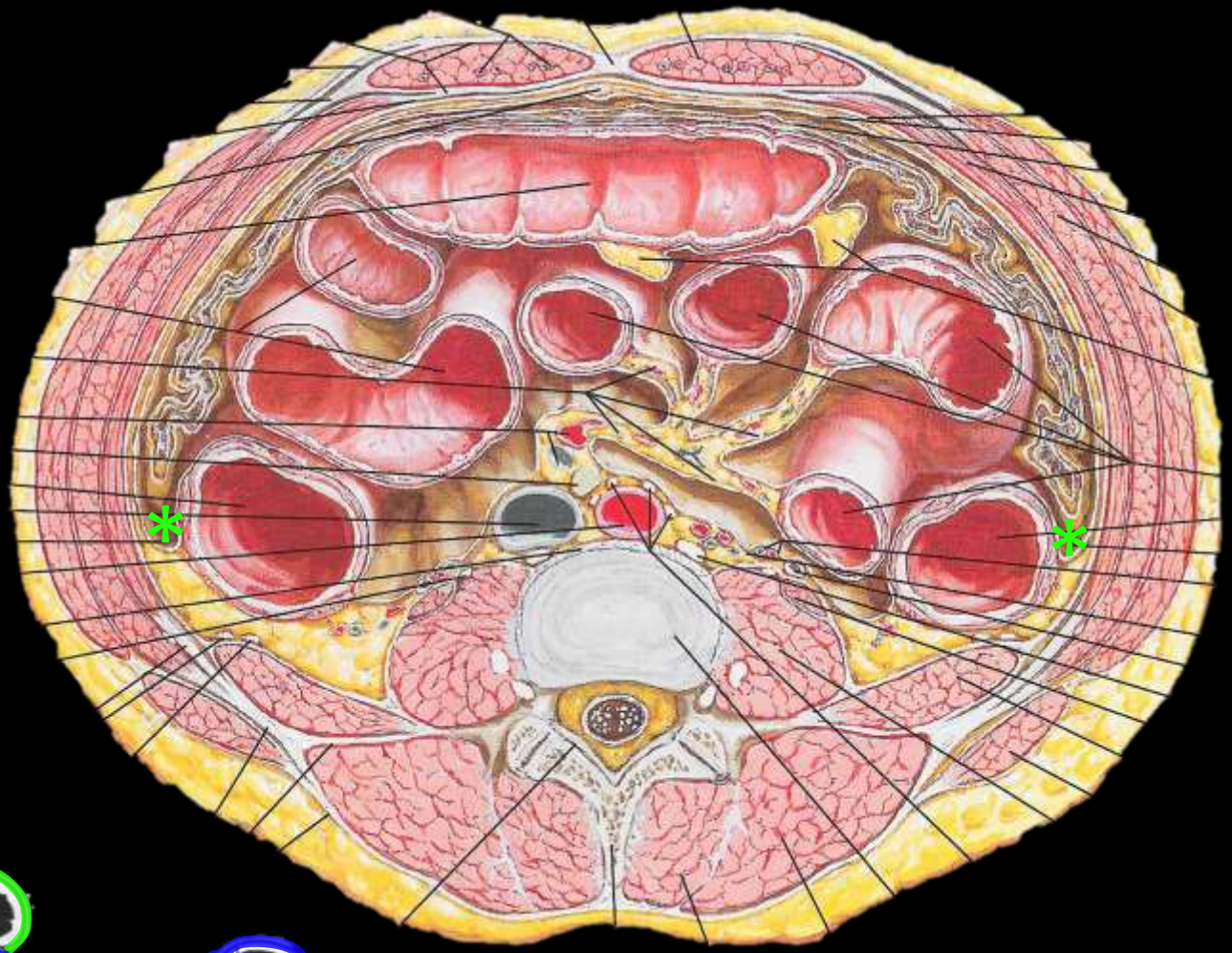

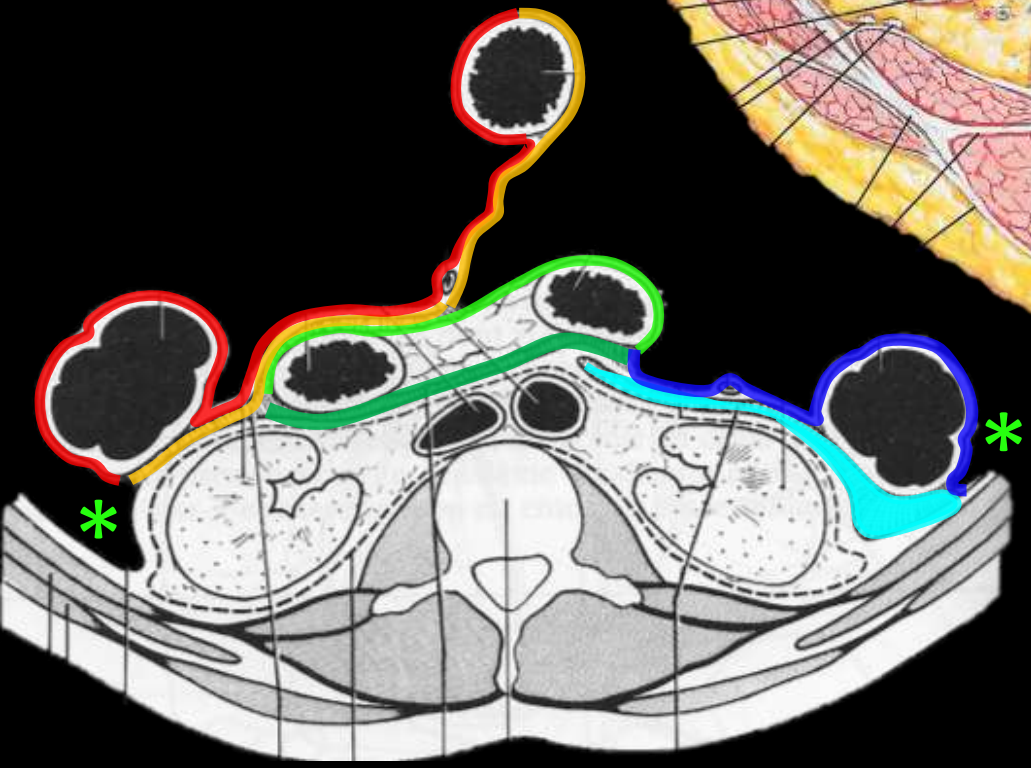

gouttières pariéto-coliques

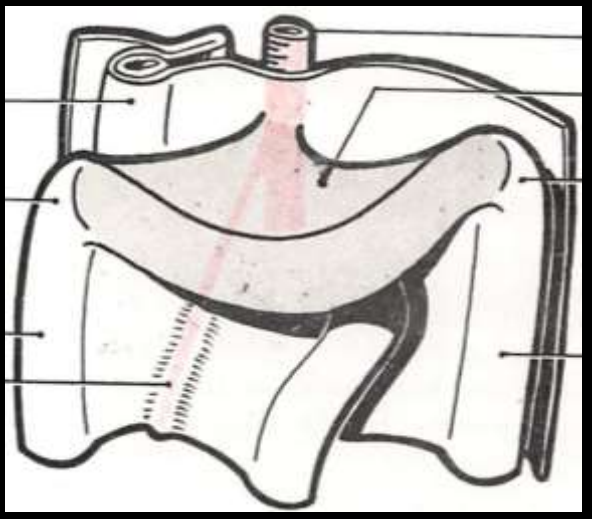

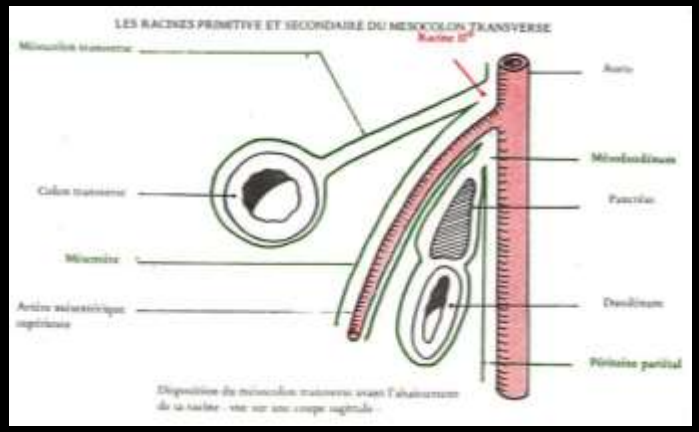
LES RACINES PRIMITIVE ET SECONDAIRE DU MESOCOLON TRANSVERSE
Mésocôlon transverse
Racine 2e
Aorte
Mésoduodénum
Côlon transverse
Pancréas
Mésentère
Artère mésentérique supérieure
Duodénum
Péritoine pariétal
Disposition du mésocôlon transverse avant l'abaissement de la racine - vue sur une coupe sagittale

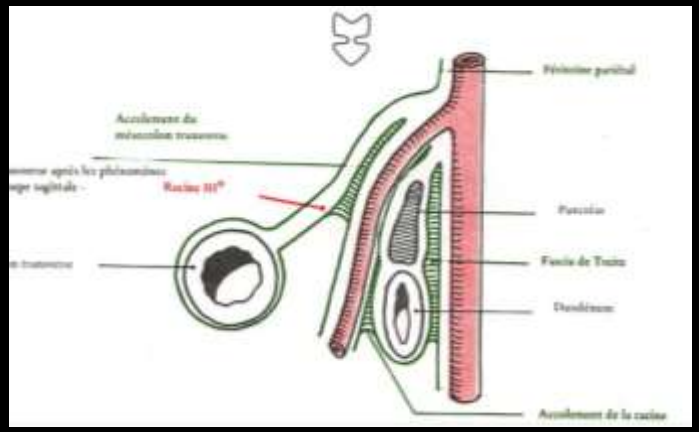
Péritoine pariétal
Accolement du mésocôlon transverse
Racine 3e
Pancréas
Fascia de Treitz
Duodénum
Accolement de la racine

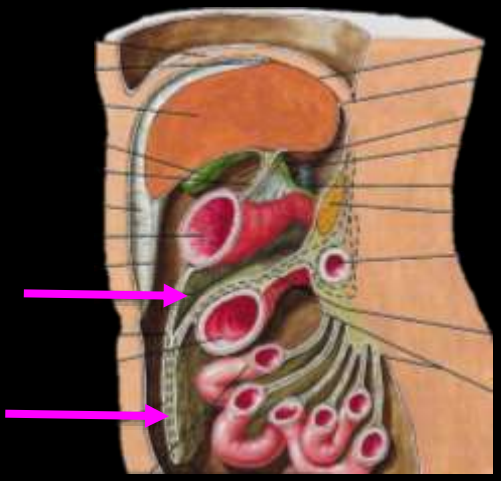

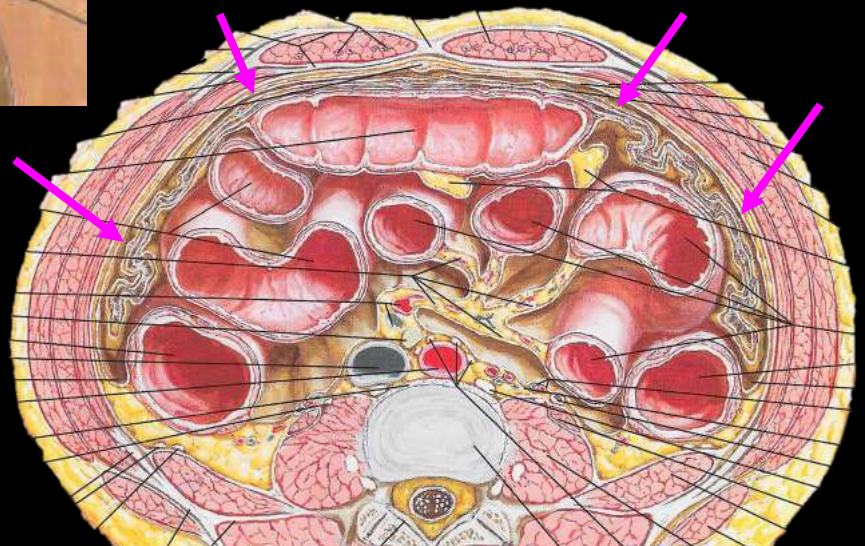

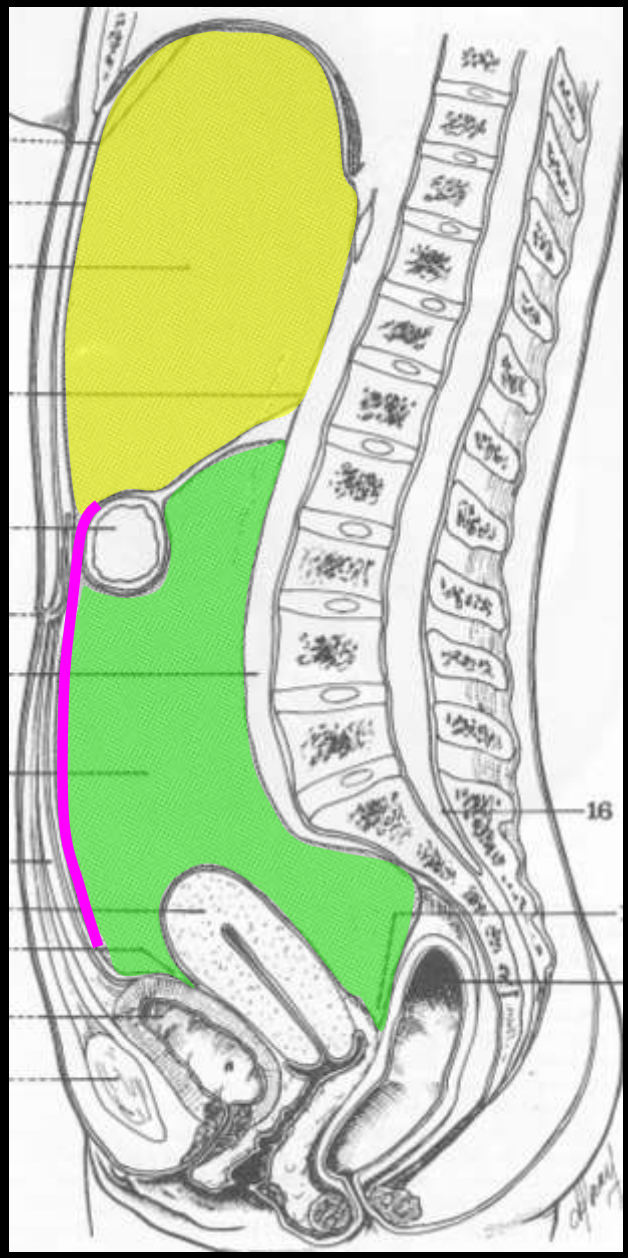
16

Etage inférieur (a. mésentérique inférieure)

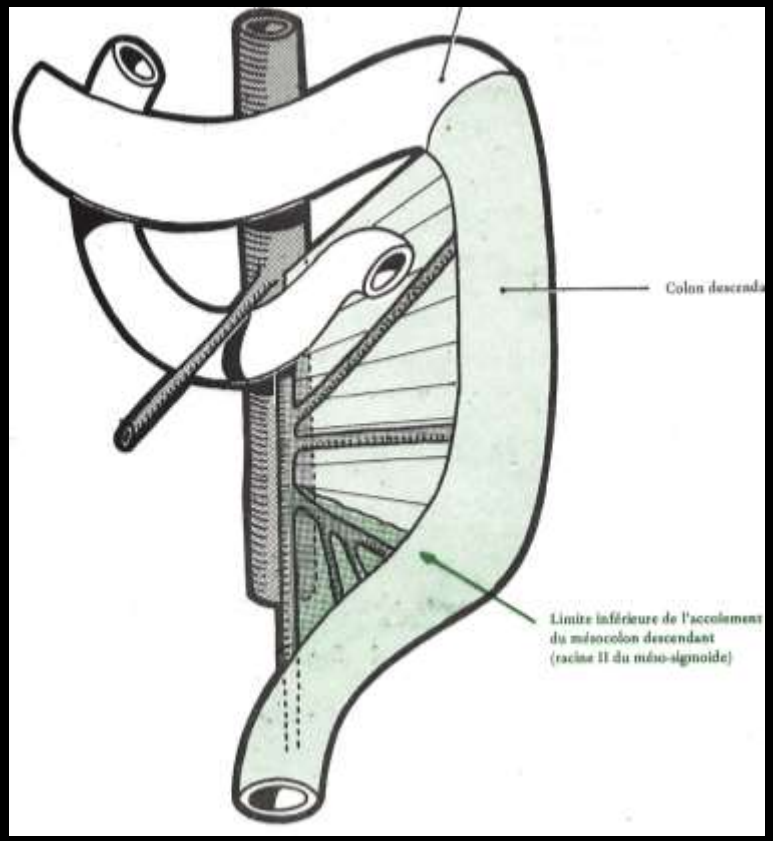

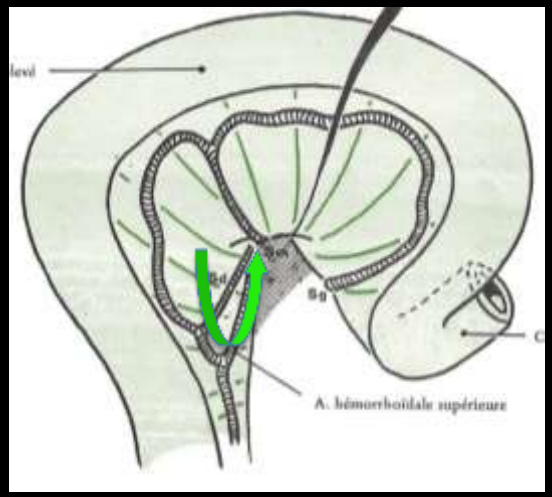

fosse inter sigmoïdienne

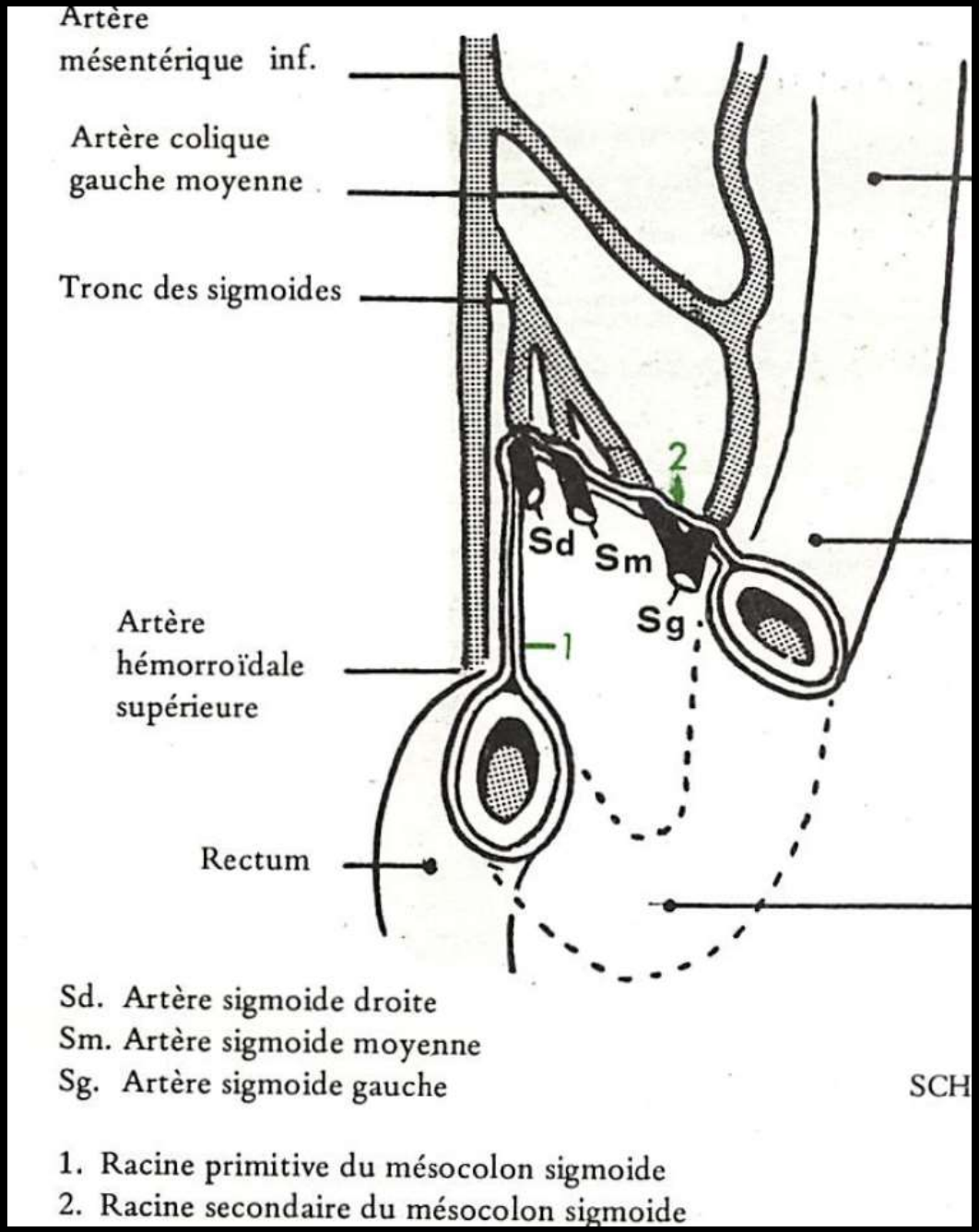

Plancher

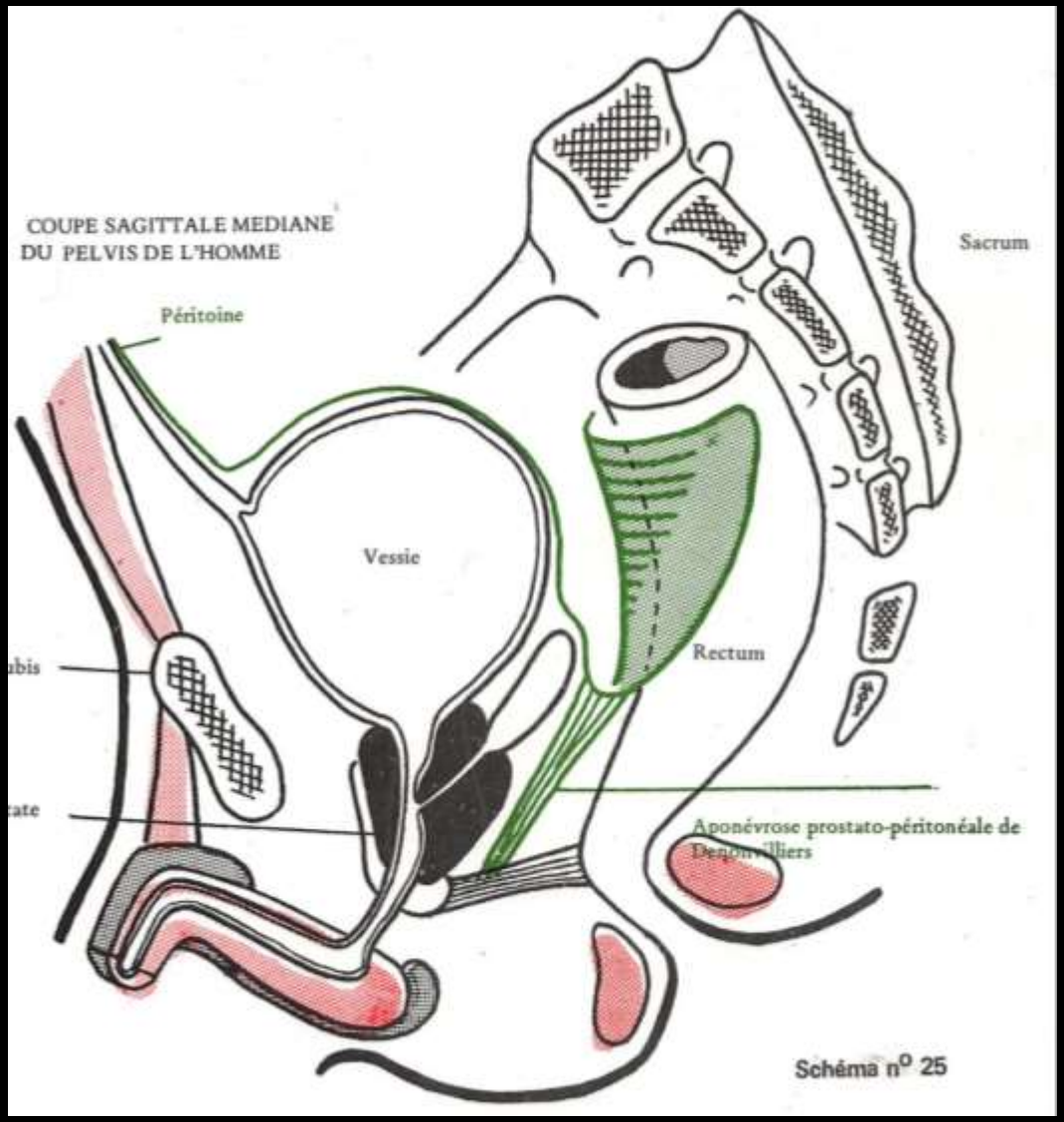
COUPE SAGITTALE MEDIANE
DU PELVIS DE L'HOMME
Péritoine
Sacrum
Vessie
Rectum
Aponévrose prostato-péritonéale de
Schéma n° 25

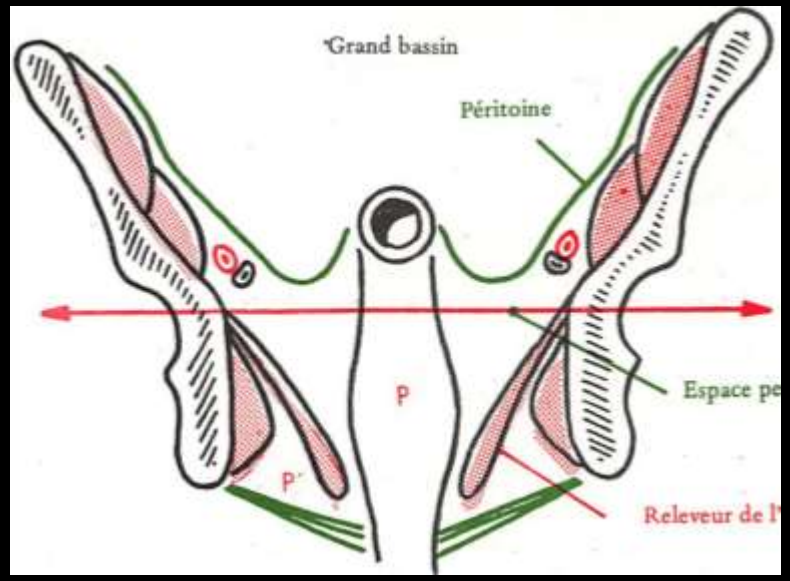
Grand bassin
Péritoine
P
P'

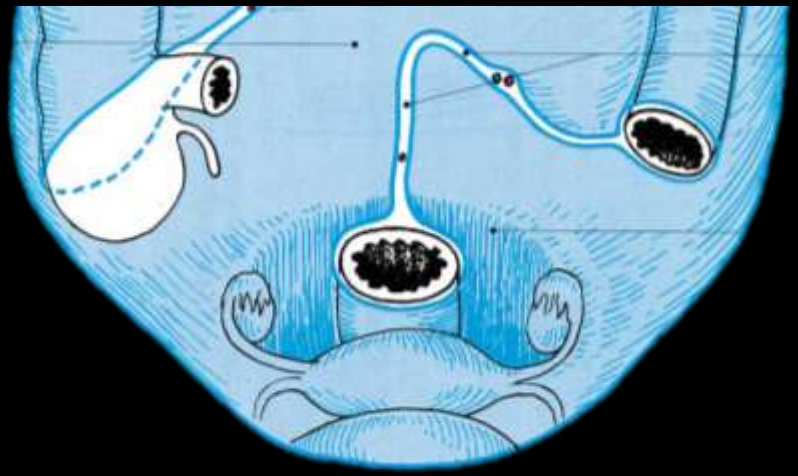

Cloisons et accolements

<u>fascia</u> : accolement postérieur du TD : fascia colique (Toldt), fascia duodéno-pancréatique (Treitz)

<u>méso</u> : entre paroi postérieure et segments non accolés du TD (mésogastre, mésentère, mésocôlon transverse ou sigmoïde), comprend des vx

<u>ligament</u> : viscère à viscère (duodéno-colique, pancréatico-splénique, gastro-splénique), viscère à paroi (falciforme), sans pédicule vasculaire majeur

<u>omentum</u> : viscère à viscère avec un pédicule gastrocolique (grand), gastro-hépatique (petit)

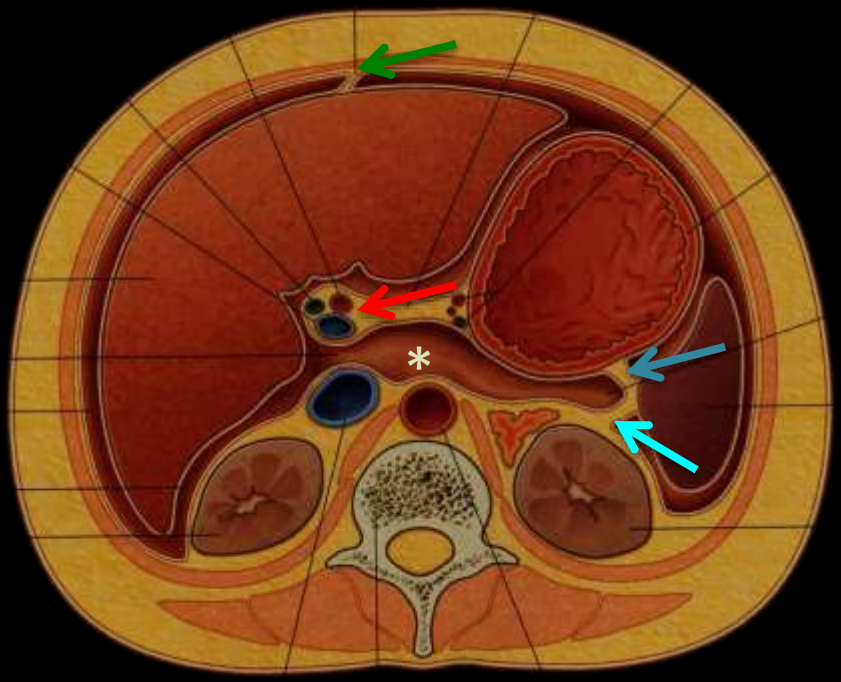

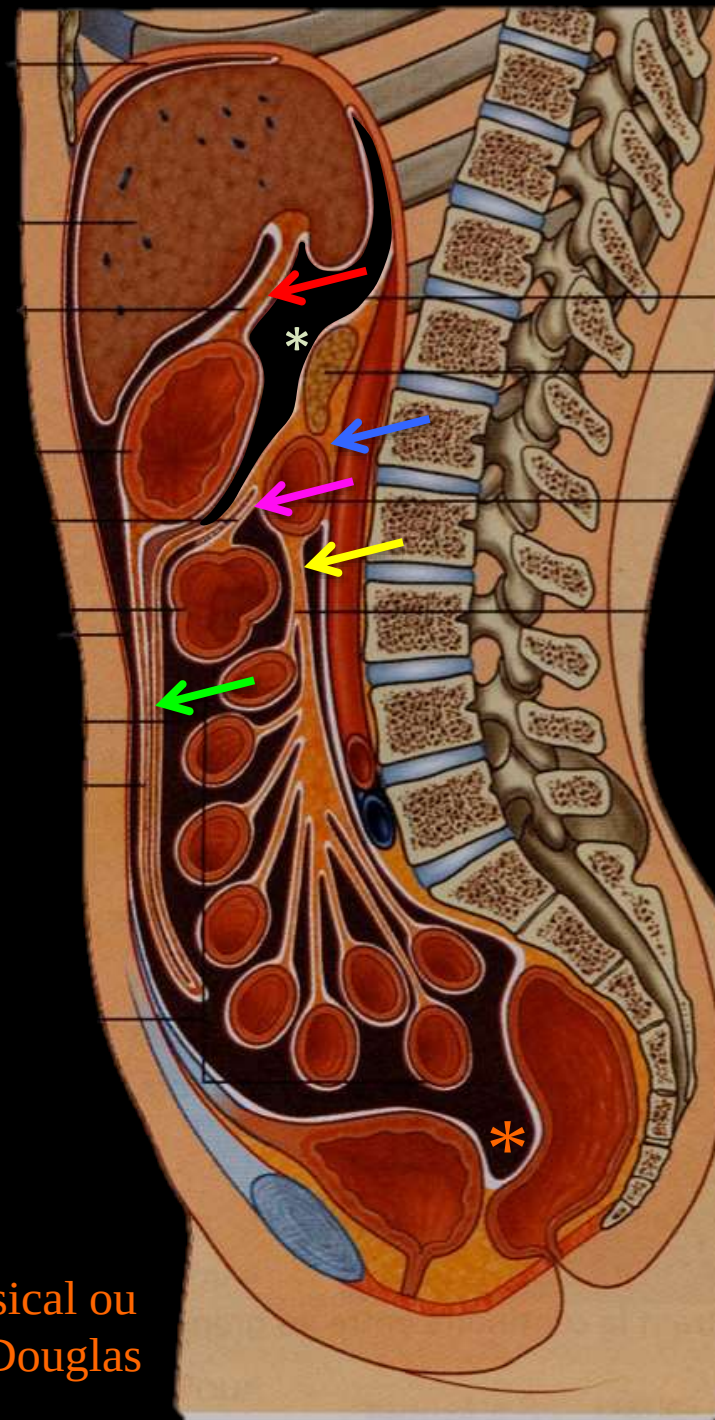

bourse omentale

recessus recto-vésical ou recto-vaginal de Douglas

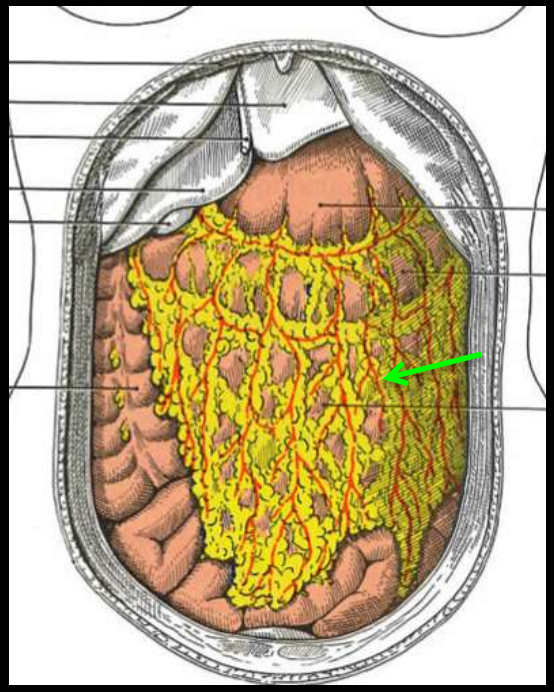

grand omentum

mésocôlon transverse
sépare les étages supra
et infra mésocoliques

mésentère

méso-sigmoïde

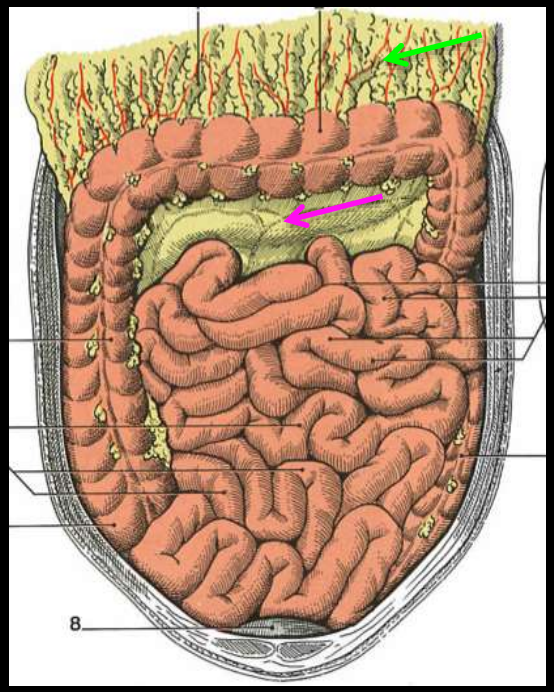

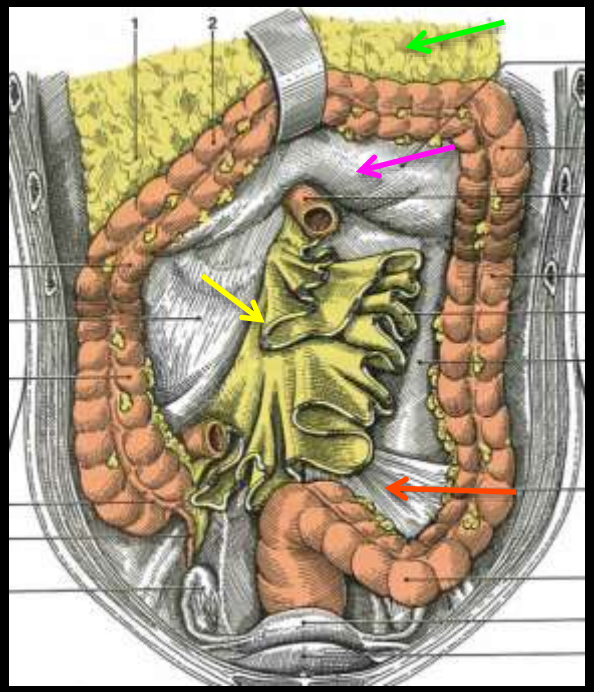

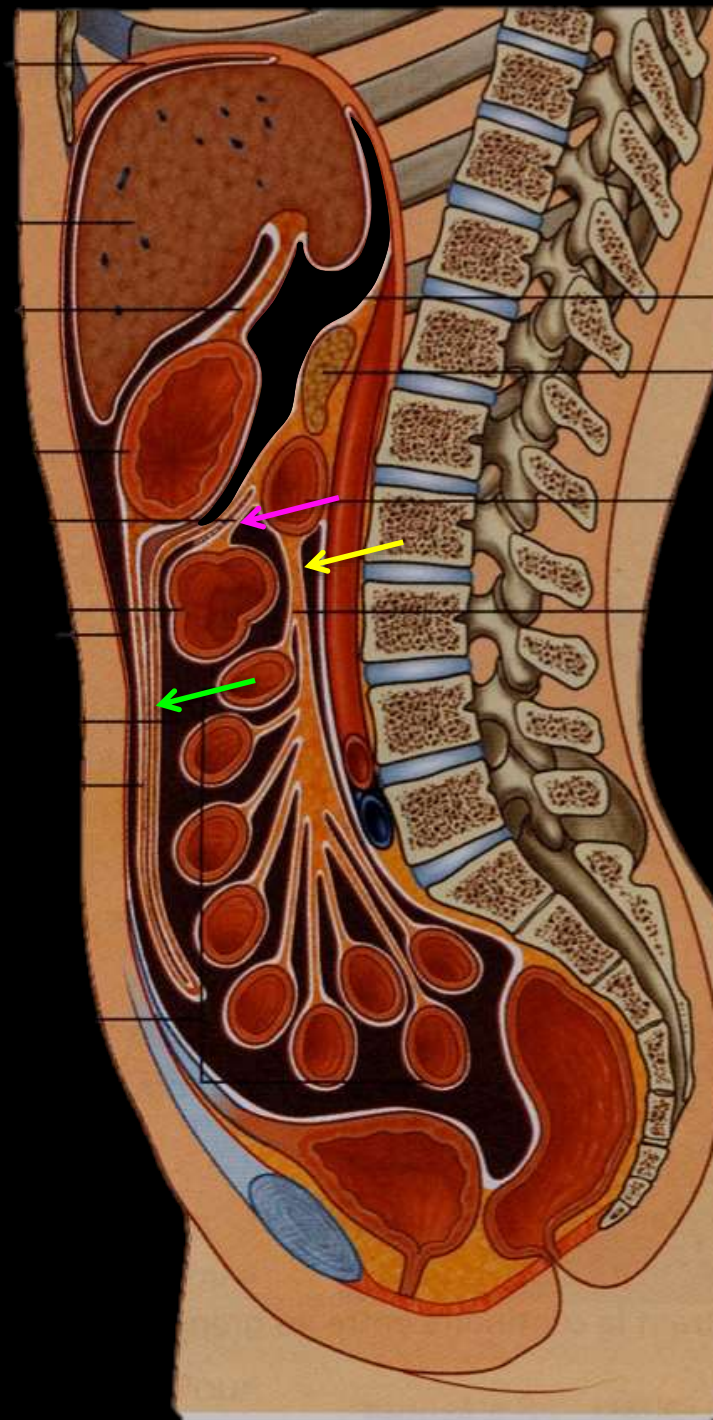

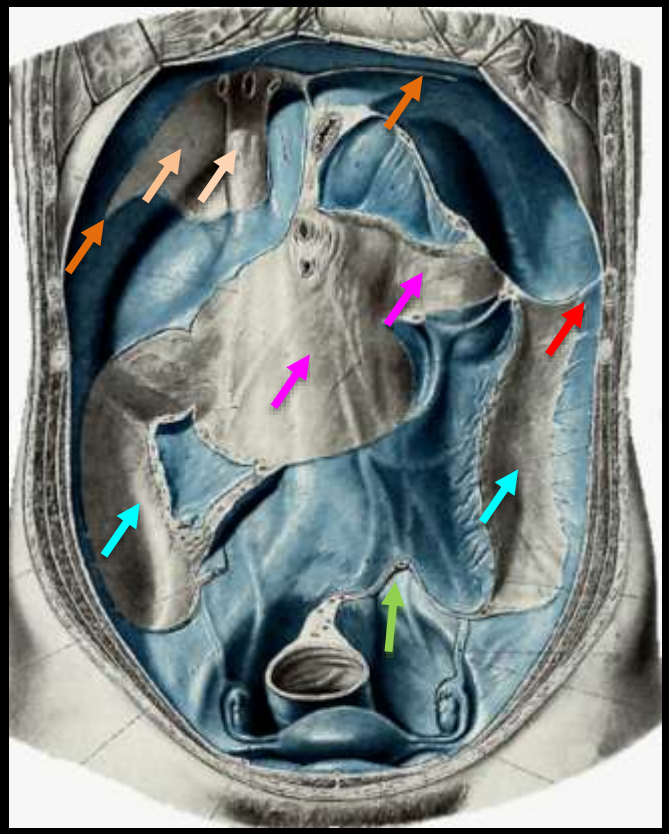

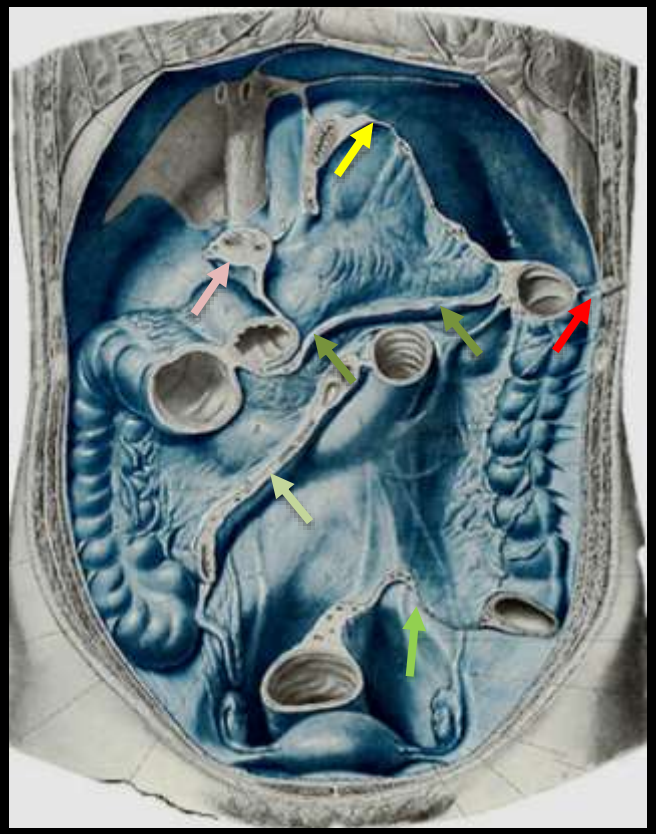

- accolement hépatiques (area nuda, l. coronaire, ll. triangulaires, ll. falciforme et rond)

- accolement gastrique (l. gastrophrénique)

- accolement duodéno-pancréatique (Treitz)

- accolements coliques D et G (Toldt)

- petit omentum

- grand omentum, l. phrénico-colique

- mésentère

- méso-côlon transverse

- méso-sigmoïde

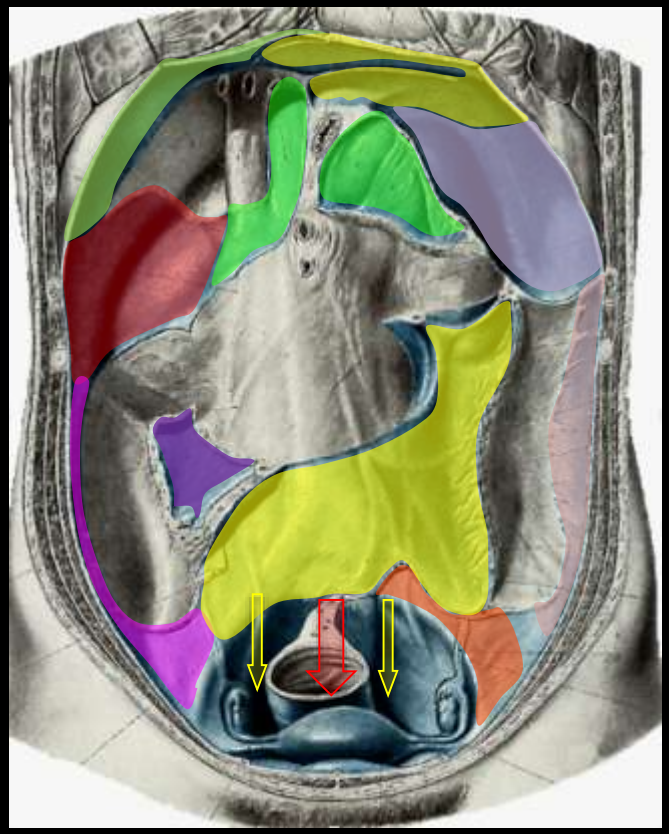

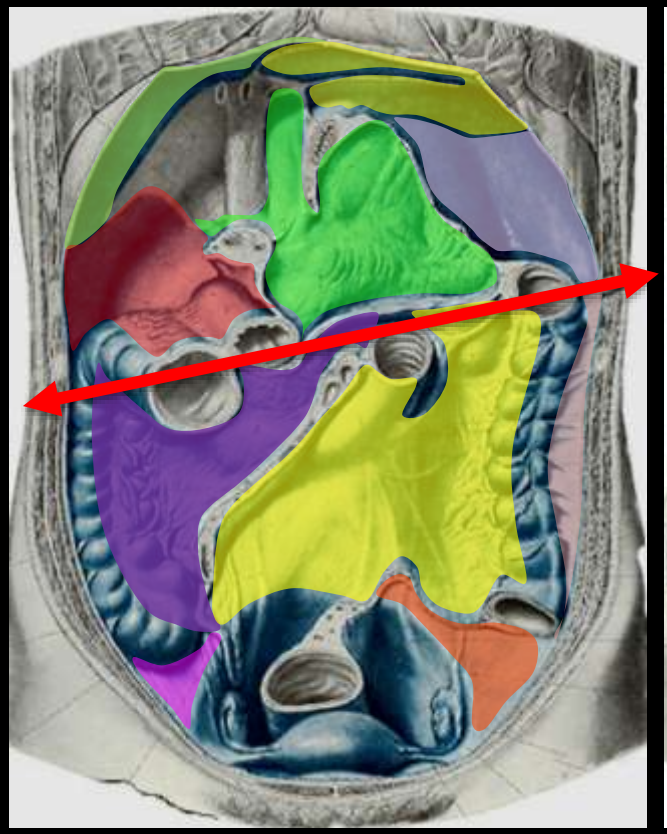

Espace sus-mésocolique

espace sous-phrénique droit

espace sous-hépatique droit
(partie postérieure: espace de Morison)

espace sous-phrénique gauche

espace sous-hépatique gauche

espace péri-splénique

bourse omentale

Espace sous-mésocolique

gouttière pariétocolique droite

gouttière pariétocolique gauche

espace sous-mésocolique gauche

espace sous-mésocolique droit

fosse inter-sigmoïdienne

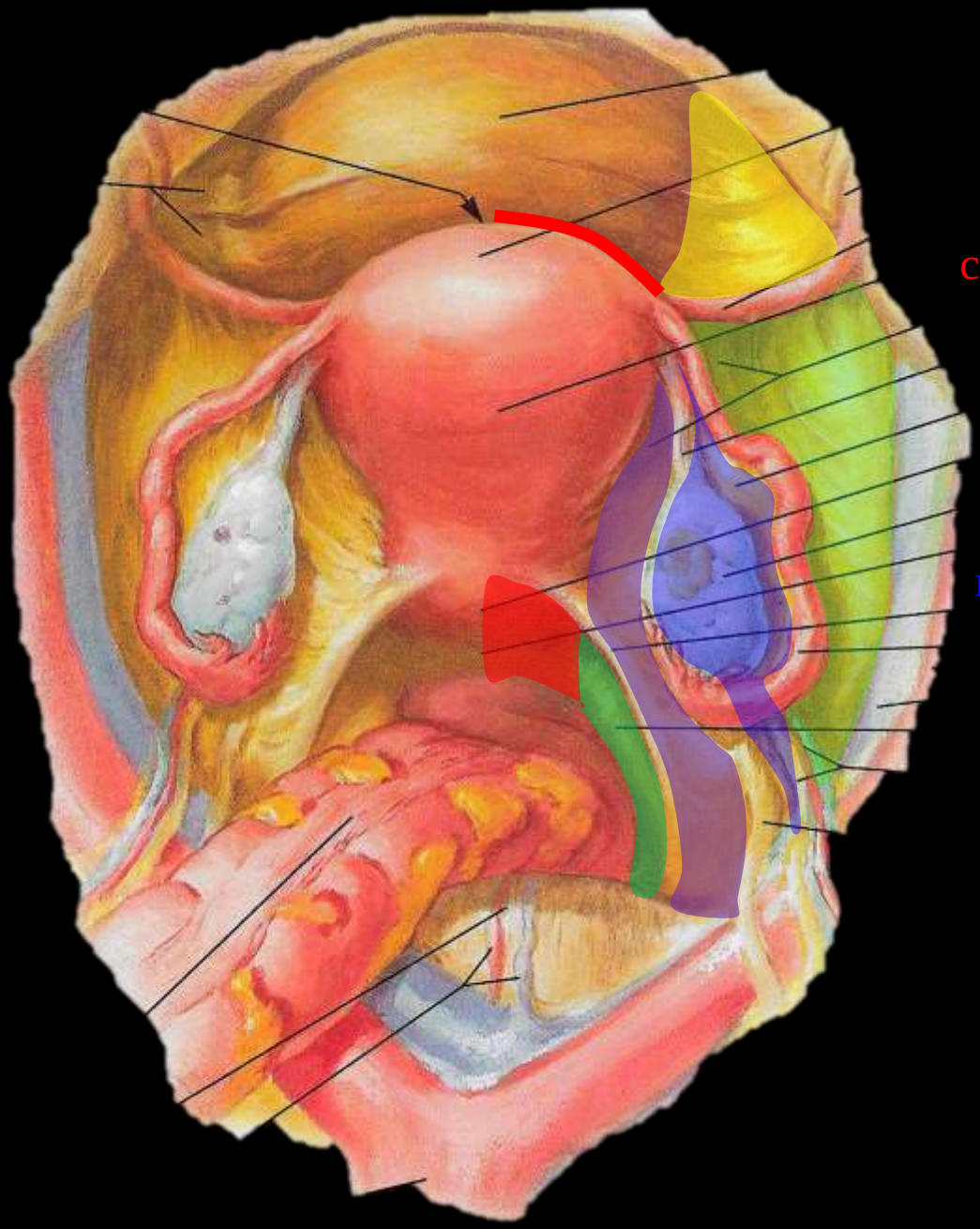
fosse para-vésicale
cul-de-sac utéro-vésical
fosse pré-ovarique
récessus tubo-ovarique
fosse ovarique
fosse para-rectale
cul-de-sac recto-utérin

Circulation du liquide péritonéal:

- gravité
- mouvements respiratoires
- résorption lymphatique (hémicoupole droite +++)

Zones déclives:

- Douglas & fosses para-rectales
- Morison

Implants péritonéaux:

Zones de stase

- Douglas & fosses para-rectales
- méso-sigmoïde
- région iléo-cæecale

Zones de fort passage
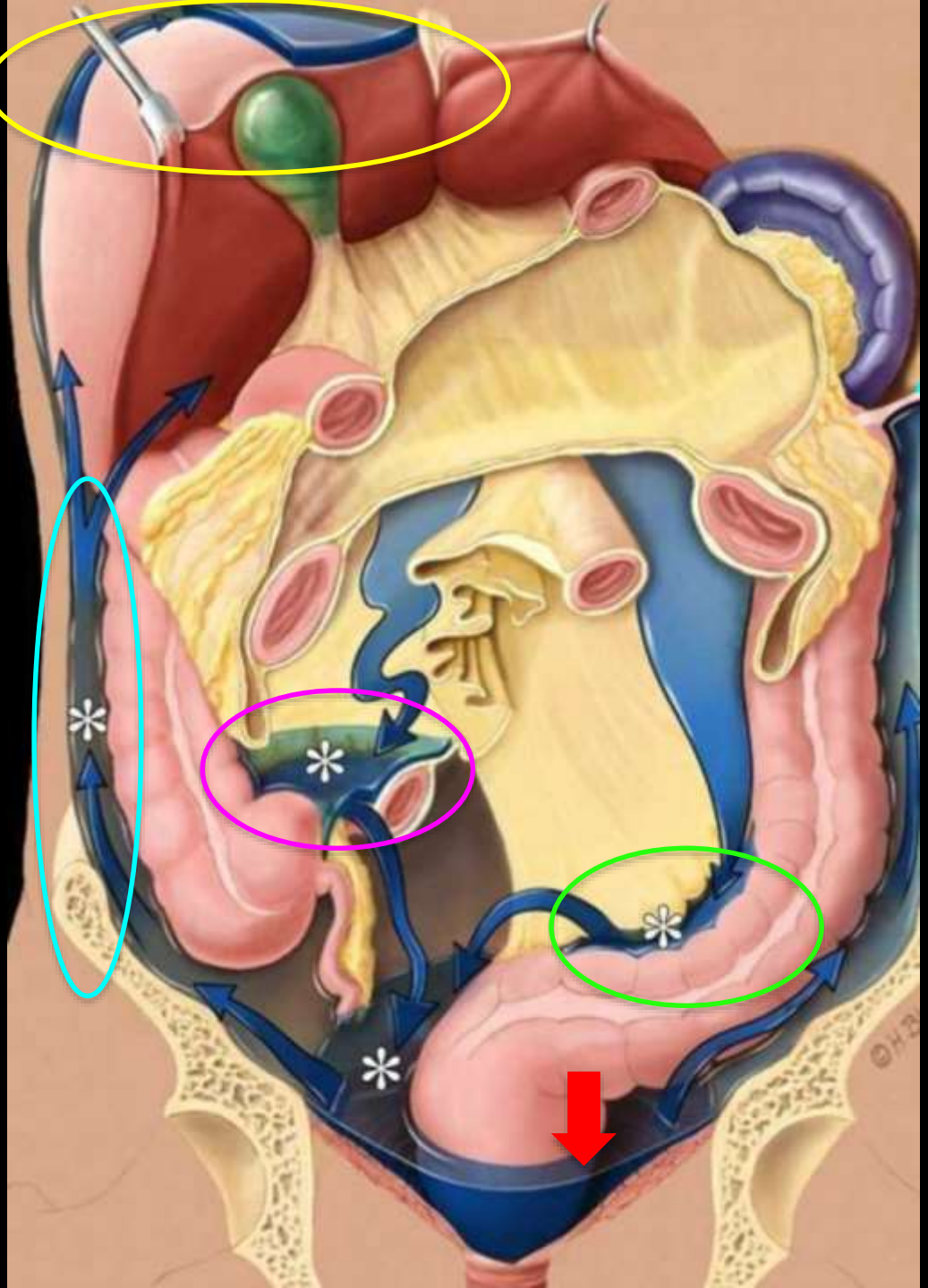
- gouttière pariéto-colique D
- hémi-coupole droite